

# ORTHONEWS

SPRING / SUMMER 2024  
VOL 1 #44

A PERIODICAL FOR ORTHODONTIC PROFESSIONALS

Leaf Expander Series

no home  
activation  
required

MORE INFO  
[LEAFEXPANDER.COM](http://LEAFEXPANDER.COM)



**LEONE S.p.a.**  
MANUFACTURING  
ORTHODONTIC  
PRODUCTS SINCE 1934

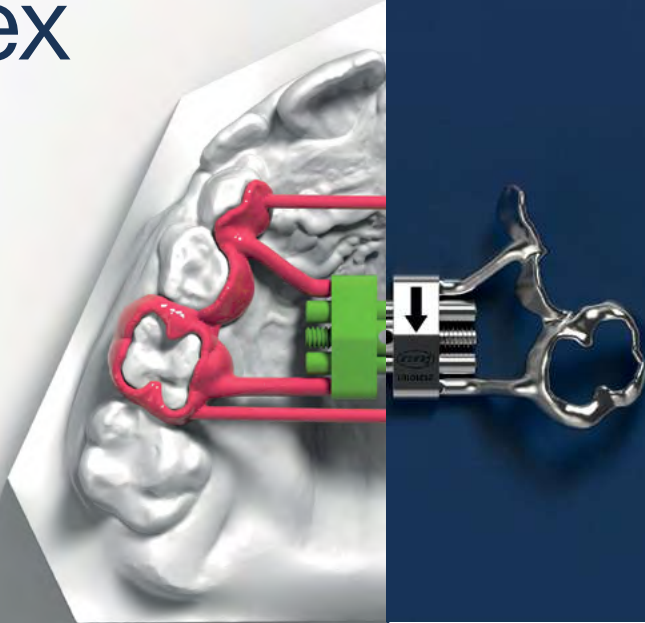

**Leone**<sup>®</sup> America

[LEONEAMERICA.COM](http://LEONEAMERICA.COM)

Introducing

 Sintex



## Fully Digital Designed Sintered Expander

## WHY SINTEX ?

Less	chair time
Better	predictability
More	comfort
Higher	reliability

**Because SINTEX** does not need either elastic separator or trial band appointments.

**Because** the bonding procedure is easier, quicker and pain free for the patient.

**Because** the **3DLeone Designer** software allows optimal biomechanical expander positioning and full customization of the framework design.

**Because** with the free Viewer you can modify and approve **SINTEX** prior to the delivery.

**Because SINTEX** is powered by Leone CAD-CAM screws, the strongest expander available and ideal for TADs, hybrid and full bone borne anchored expanders.



FULL LIST OF LABS USING **3DLEONE DESIGNER** SW AND THE DEDICATED **LEONE CAD-CAM** SCREW SERIES ON [WWW.LEONEAMERICA.COM](http://WWW.LEONEAMERICA.COM)

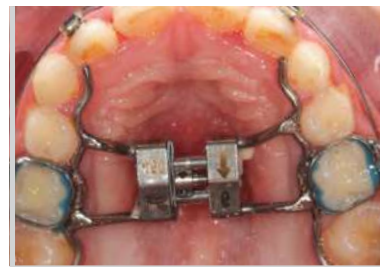**Leone**<sup>®</sup> America

(805) 487-9860 | [info@leoneamerica.com](mailto:info@leoneamerica.com)

**THE LEAF EXPANDER: EASY, COMPLIANCE FREE,  
RELIABLE AND NONINVASIVE TREATMENT OF CROSSBITE  
IN PEDIATRIC ORTHODONTICS**

Ferro R.

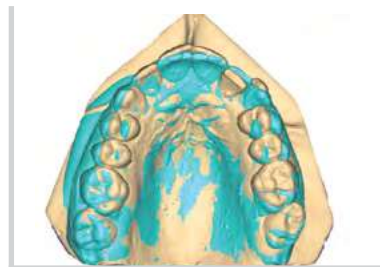
pag. 4



**THE LEAF EXPANDER FOR THE TRANSVERS MAXILLARY  
CORRECTION IN ADULT PATIENTS**

Caburlotto A., Grecolini M. E., Lanteri V.  
Matacena G, Nocco C.

pag. 17



**LEONE ORTHODONTIC SYMPOSIUM:  
CONTEMPORARY METHODS FOR SPACE-GAINING**

pag. 29

**CONTEMPORARY  
METHODS FOR  
SPACE GAINING**

**WHERE TO FIND US:  
LEONEAMERICA COLLABORATIONS**

pag. 31

# THE LEAF EXPANDER®: EASY, COMPLIANCE FREE, RELIABLE AND NONINVASIVE TREATMENT OF CROSSBITE IN PEDIATRIC ORTHODONTICS

**Roberto Ferro**

Odontostomatology and Orthognathodontics, Cittadella Padua Italy

Free translation from: IL LEAF EXPANDER: IL TRATTAMENTO SEMPLICE, NON COMPLIANCE, EFFICIENTE E NON INVASIVO DEL MORSO CROCIATO IN ORTODONZIA PEDIATRICA, Roberto Ferro Odontostomatology and Orthognathodontics, Cittadella Padua Italy

“

The purpose of this article is to present a small preview of the atlas, redacted by Dr. Ferro, that will be published in 2024 about the Leaf Expander. The author has collected several clinical cases with different types of transversal deficits, malocclusion class and dentitions, thus to allow clinicians, through keywords, to identify similar cases to the ones that they might have to deal with.

On the atlas, all the medical records are included, while for the purpose of this article, only before/after pictures are reported.

**Editor's note**

”

---

## **AUTHOR'S PREFACE**

### ***Orthodontic Mainstream, the Dominant Orthodontic Thought Nowadays***

*Since years, social media and training offers are widely talk about an aligners orthodontics. Moreover, it has added an orthodontics which “cannot move forward” without the TADs utilization, even to solve a transversal discrepancy in mixed dentition.*

*Despite this, exists an easy orthodontics, cheap, extremely effective where the orthodontist does not work as “an employee of aligners manufacturing company”, but thinks by himself.*

*This is the orthodontics for growing patients, which is not definitely the aligners one like many people tend to claim, but the one which exploits simple appliances, effective and cheap, as the three cases I am going to share with you in this article.*

---

## INTRODUCTION

In this preview of the atlas, three clinical cases in mixed dentition have been reported, all three cases required a maxillary expansion. The first one is related to a functional posterior crossbite solution, in the second one a Class II malocclusion (second division) with a bi-lateral crossbite was solved; the third one, proves the success of a functional anterior crossbite.

For all three cases, the Leaf Expander model used was the one that delivers 450g and reaches 6 mm of expansion and the malocclusion was solved on about 3 to 4 months in total. The leaf expander is gradually becoming the first-choice method for the author, progressively replacing the standard rapid palatal expander, to solve the orthodontic discrepancy on the transversal plane.

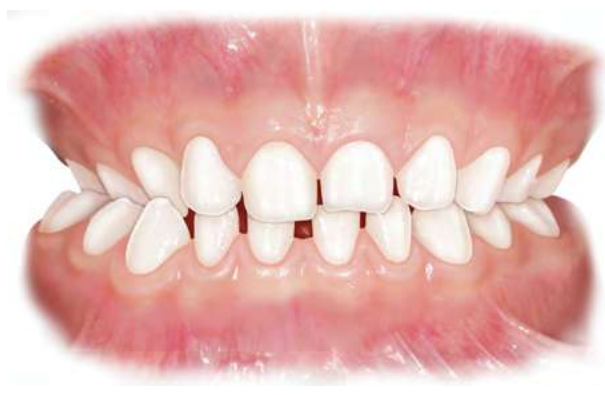

FIG. 1 - Mono-lateral right crossbite in deciduous dentition. Drawing from the book "Deciduous dentition: where the orthodontic starts" author: Roberto Ferro, Ed. Martina- Bologna 2022

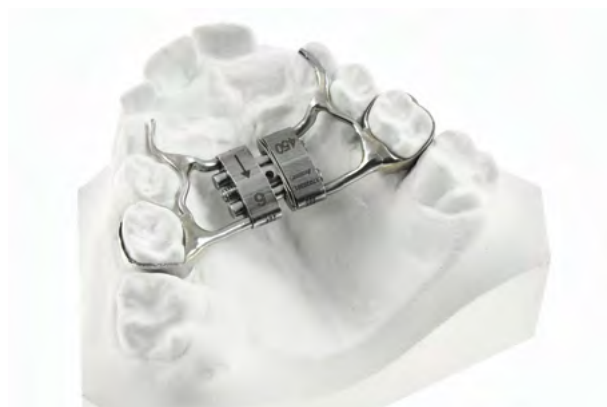

FIG. 2 - Leaf expander

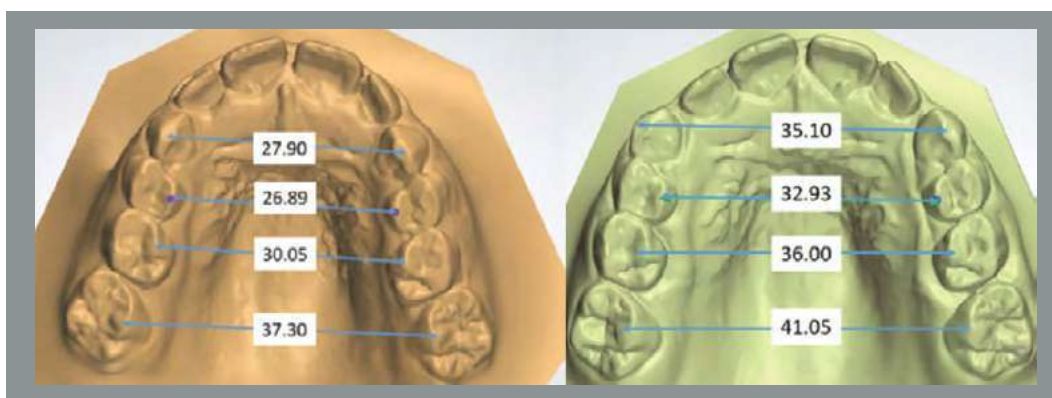


FIG. 3 - Courtesy of Valentina Lanteri, DDS

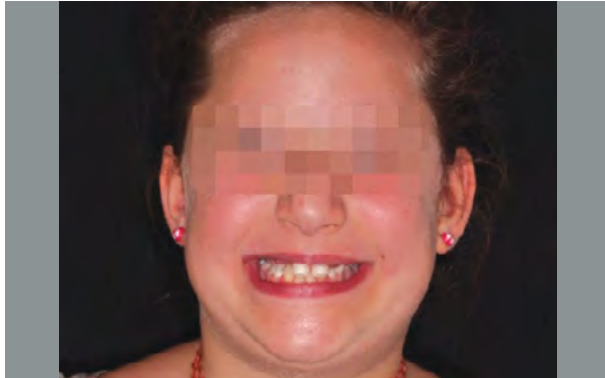The superimposition of the 3D models (Study conducted on 10 patients in mixed dentition) after the treatment with the leaf expander 450g, 6mm designed on the E elements, is shown a constant increase in transverse diameters, from C elements to E elements; due to the remodeling of superior maxilla, the increase at the molar level is less than increment of the anterior portion, as happens in RPE treatment (Lanteri V., 2017, 2018).

## CASE 1

### Joanna, 8/9 years- Use of the Leaf expander to correct a functional Posterior Crossbite

9 year old girl, almost in permanent dentition, Molar occlusion Class I on the left, shifted midline, lateral posterior crossbite on the right from the incisor to the molar (Class II on the right is a sub-division, as a consequence related to the functional issue). Treated with Leaf Expander 450g, 6 mm, cemented on the first molar and, after 1 month, an addition of 2x4 multibrackets appliance. The treatment lasted 4 months overall and the patient is controlled with follow-up visits every 4 months. The Patient is now in permanent dentition and both, patient and parents are satisfied with the final result of the treatment.

#### SEPTEMBER 2018



FIGG. 4a-d: clinical and Intraoral pictures before the treatment

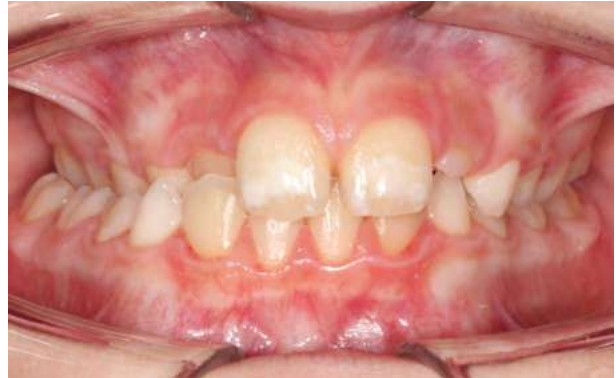

FIG. 4b

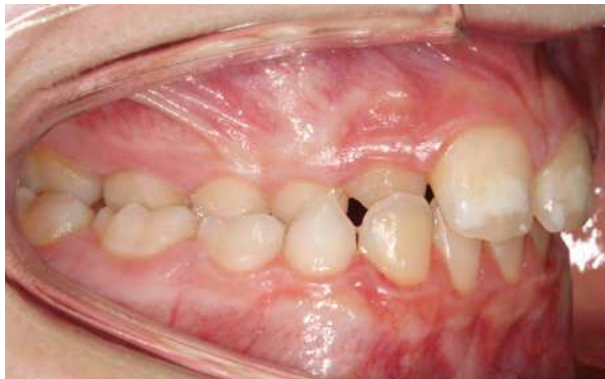

FIG. 4c

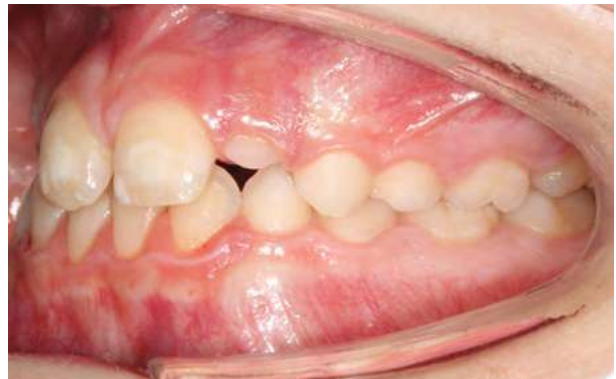

FIG. 4d

#### FEBRUARY 2019

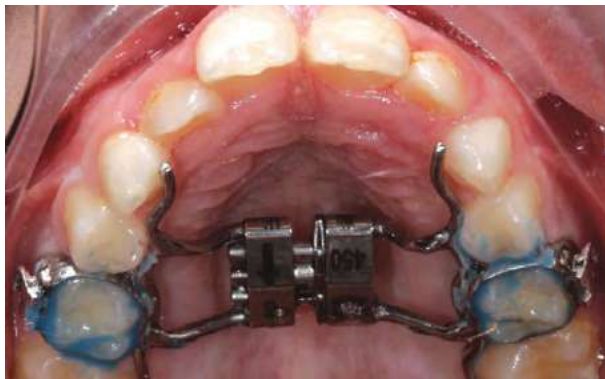

FIG. 5 - Leaf expander cemented on molars (450g, 6mm)

#### APRIL 2019

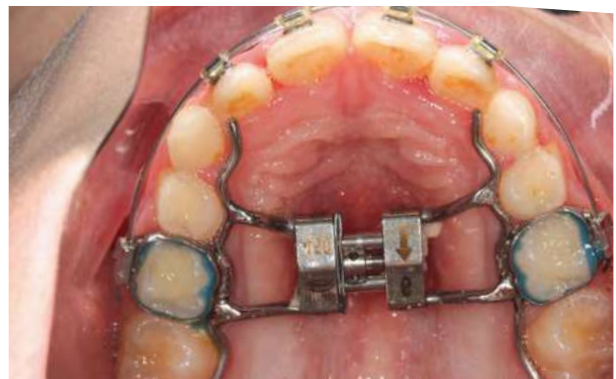

FIG. 6 - Total leaf expander re-activation, (2 months wait for the pre-programmed expansion)

**JUNE 2019**

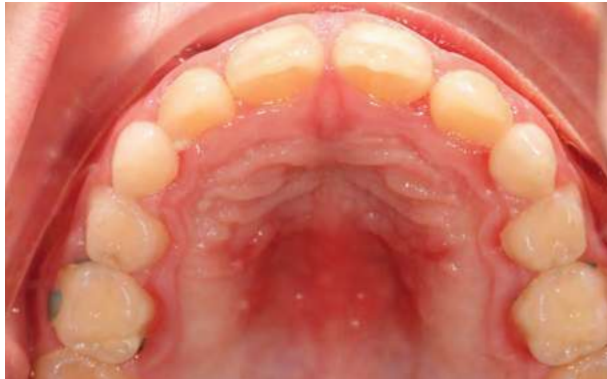

FIG. 7 - After 4 months it is possible to remove both the appliance and the brackets. No retainers are used. A slight slicing of the inferior arch has been made.

**SEPTEMBER 2021**

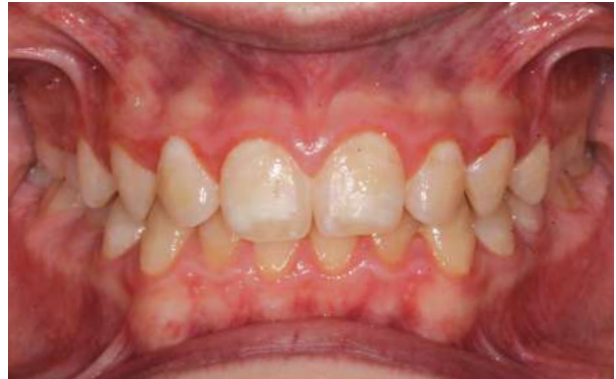
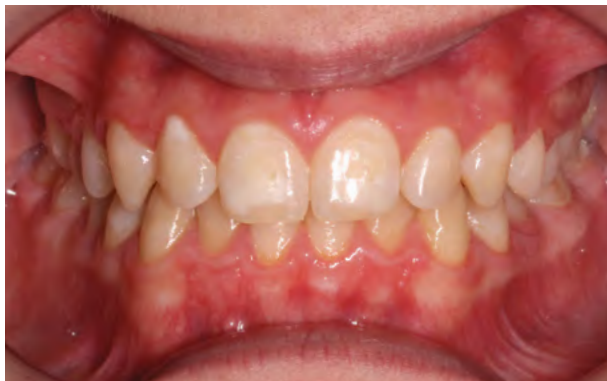
FIG. 8 - Waiting for the 75 to change, Gingivitis due to poor oral hygiene

**NOVEMBER 2022**



FIGG. 9a-c - Permanent dentition, treatment lasted for 4 months.

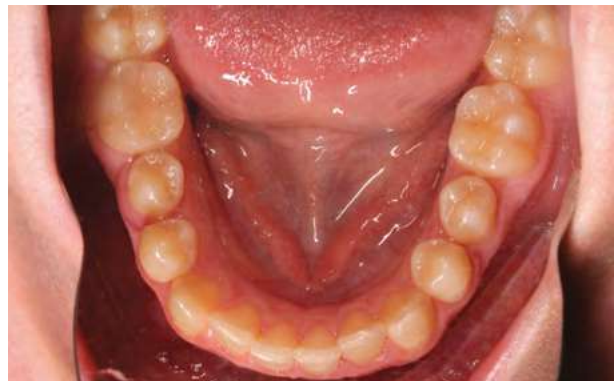

FIG. 9b

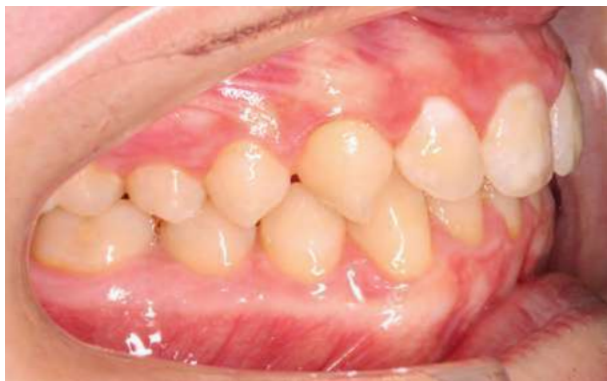

FIG. 9c

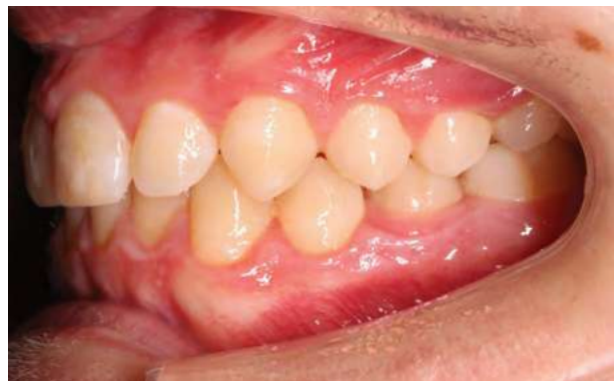

FIG. 9d

**COMPARISON: BEFORE AND AFTER THE TREATMENT**

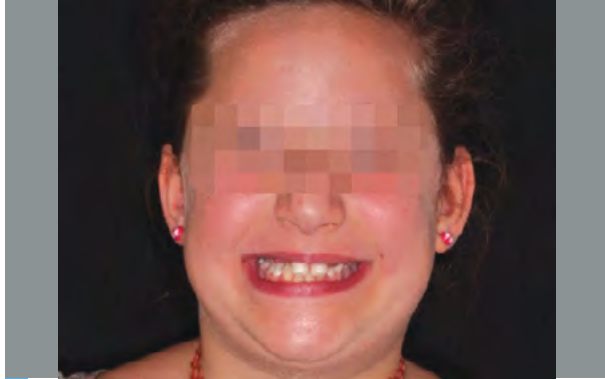
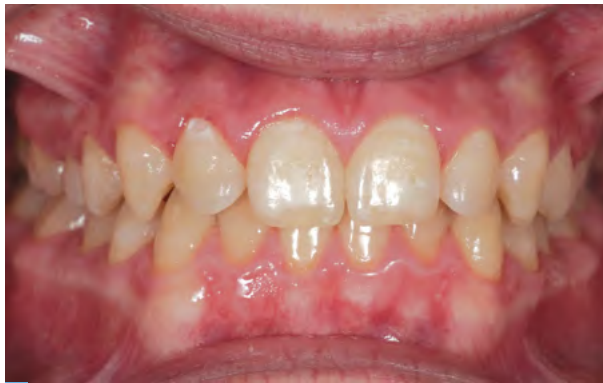
FIG. 10 - February 2019: before the treatment



FIG. 11 - November 2022, after the treatment, permanent dentition

**JULY 2023**



FIGG. 12a-c

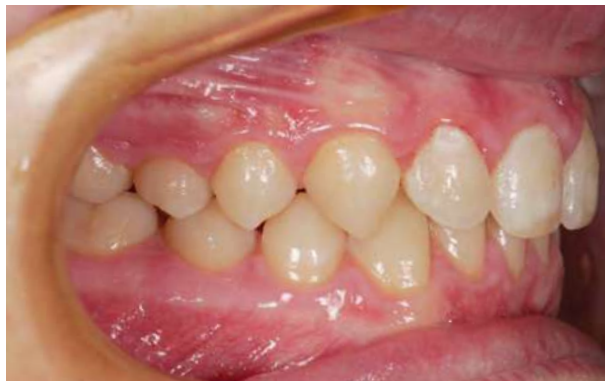

FIG. 12b

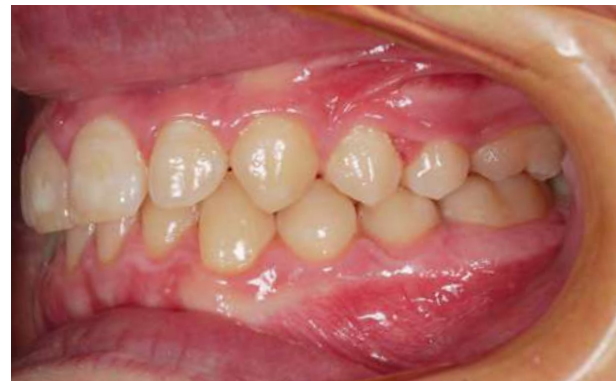

FIG. 12c

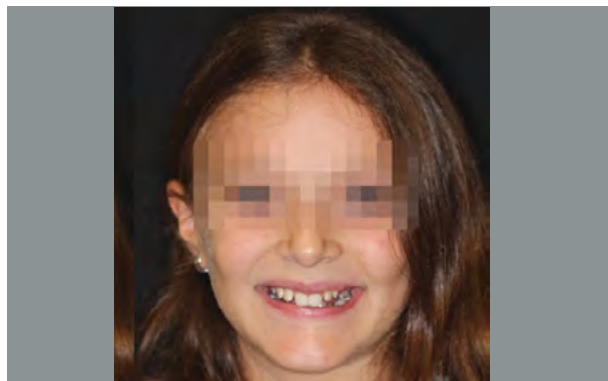

## CASE 2

### Gloria 11 year; Use of the Leaf expander in a more complex treatment

11 years old girl, third stage of the transition period, presents a Class II-division 2, subdivision left, with molar crossbite and lower jaw crowding of 7mm. At the beginning, upper arch treated with Leaf expander 450g, 6mm and lower arch with appliance similar to “Clark Transforce”, to obtain more space in the anterior sector through the increase of the inter-canine diameter. After 4 months the leaf expander has been removed and, once the lower alignment has been completed with the “similar Transforce”, a fixed appliance treatment begun with STEP system technique. After 2 years, the case is cleverly resolved, stable in time thanks to removable retainers (Van der Liden appliance for the upper arch and Hawley appliance for the lower arch).

MARCH 2019



FIGG. 13a-f - Clinical pictures before the treatment

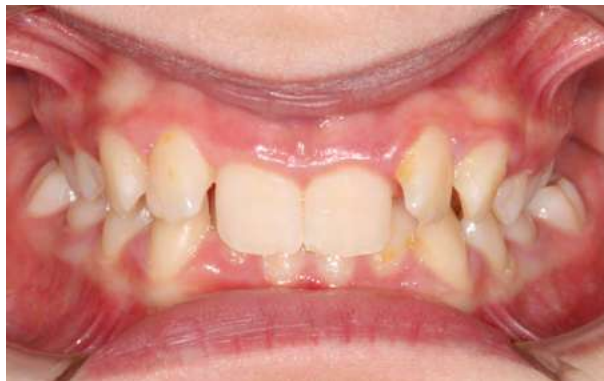

FIG. 13b

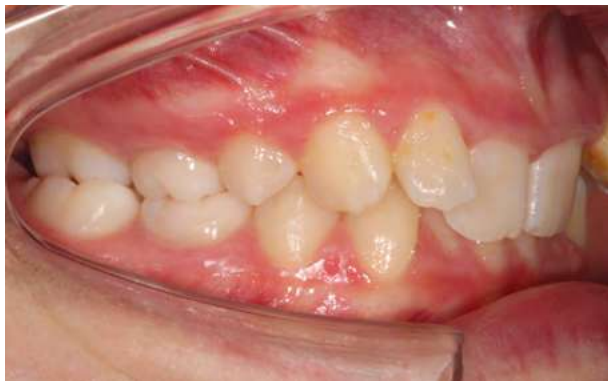

FIG. 13c

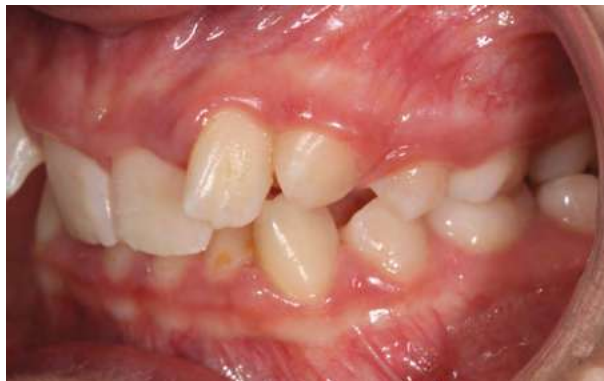

FIG. 13d

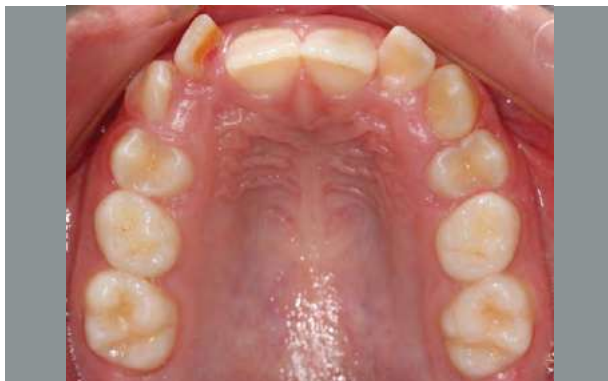

FIG. 13e

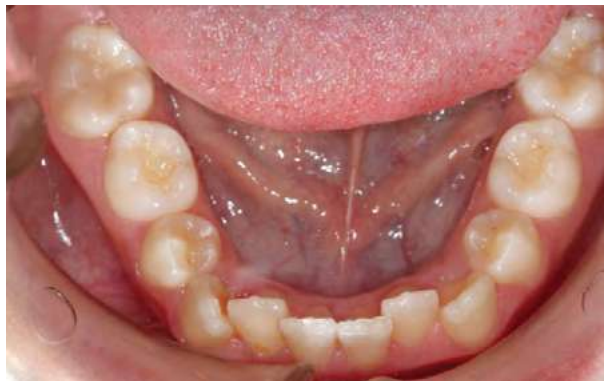
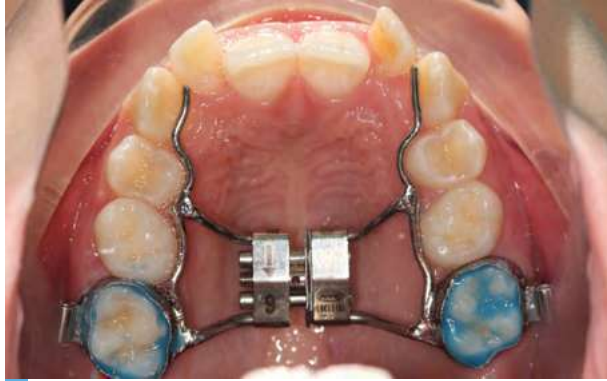
FIG. 13f

**MARCH 2019**



FIGG. 14a, b - Cementation of the Leaf expander, 450g, 6mm

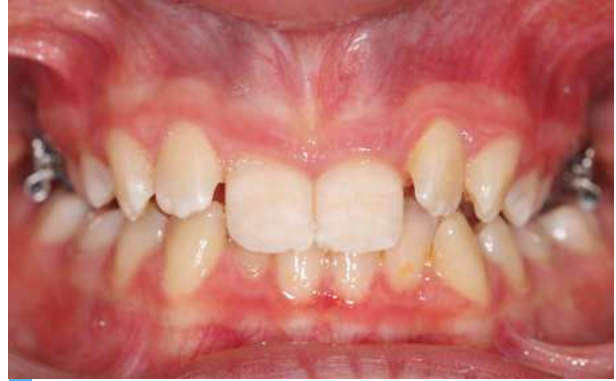
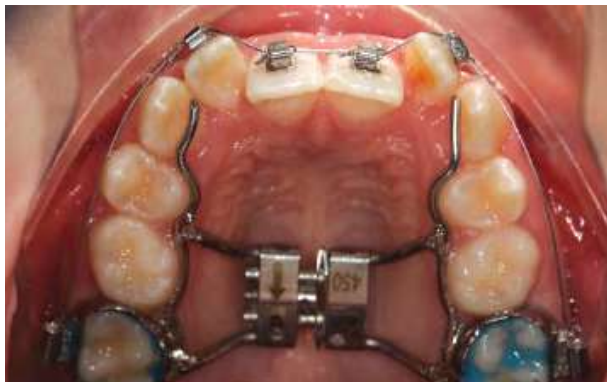
FIG. 14b

**APRIL 2019**



FIGG. 15a, b - Addition of 2x4 with Ni-Ti arch .012"; the leaf springs are not completely open

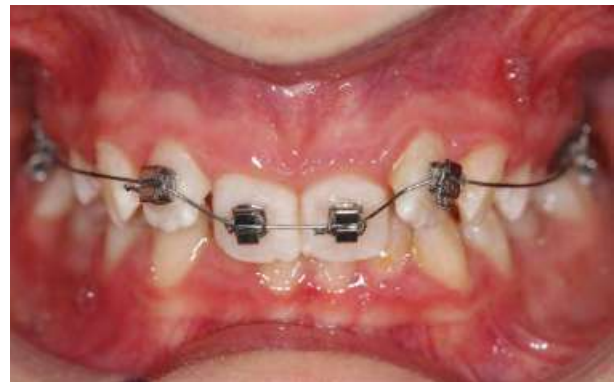

FIG. 15b

**MAY 2019**

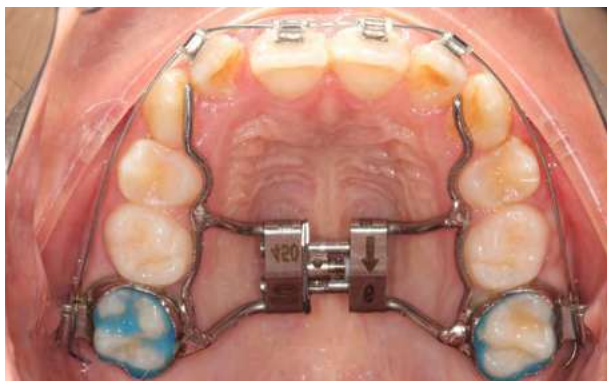

FIG. 16 - The leaf expander is activated

**JUNE 2019**

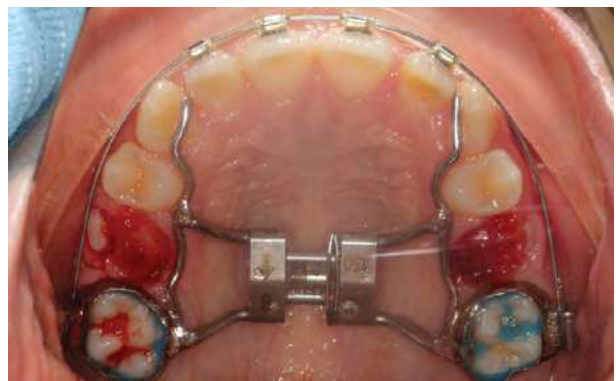
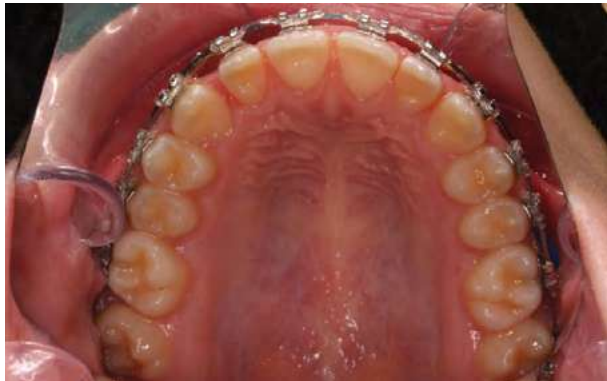
FIG. 17 - 55 and 65 extraction and Leaf expander removing (teeth are aligned.)

**JANUARY 2021**



FIGG. 18a, b - During the stage with TBK elastics

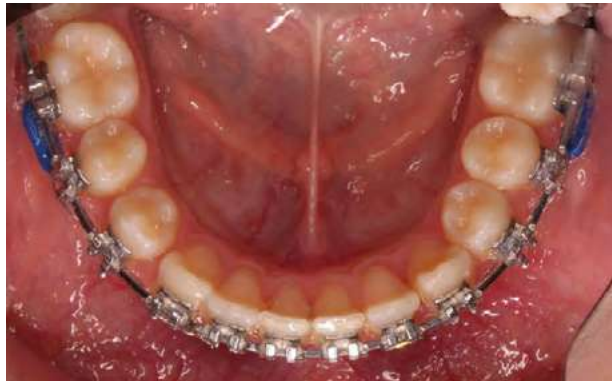
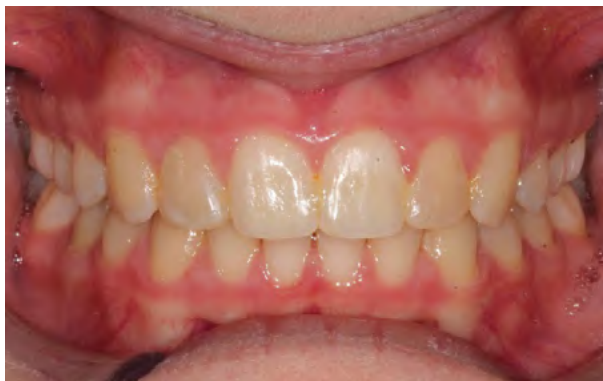
FIG. 18b

**MARCH 2021**



FIGG. 19a-g - End treatment

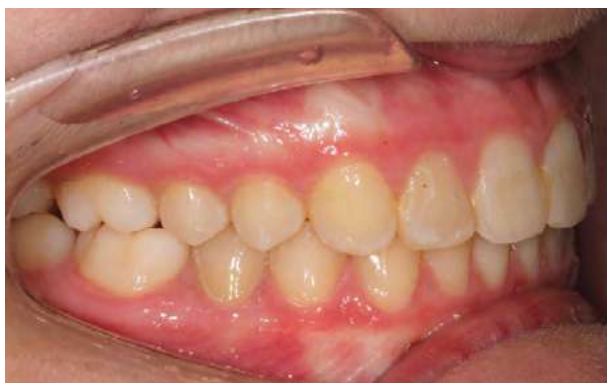

FIG. 19b

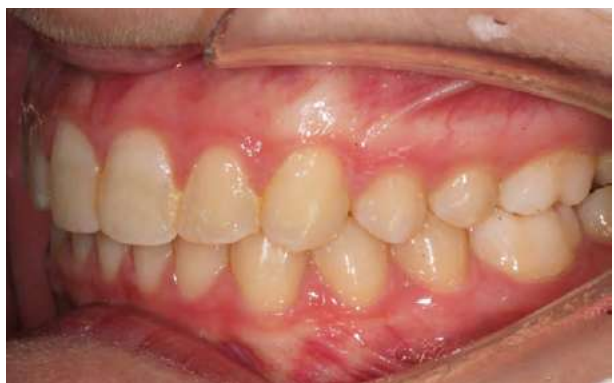

FIG. 19c

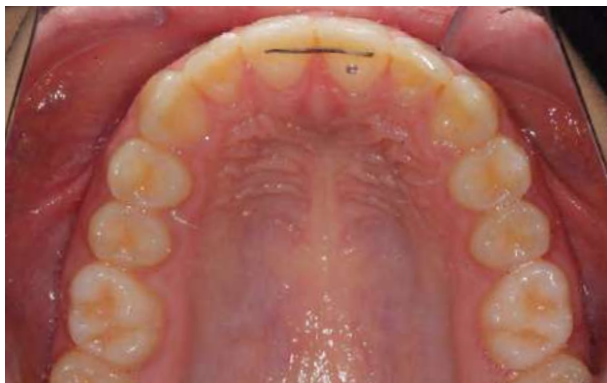

FIG. 19d

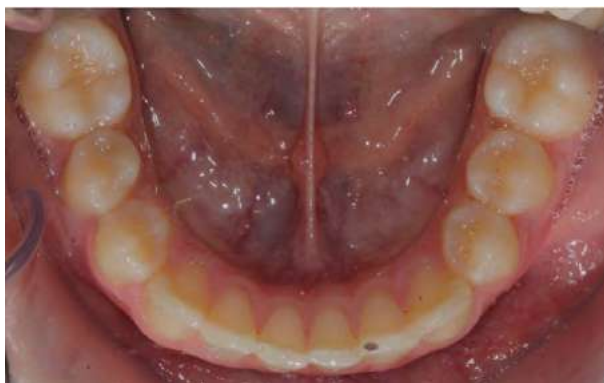

FIG. 19e

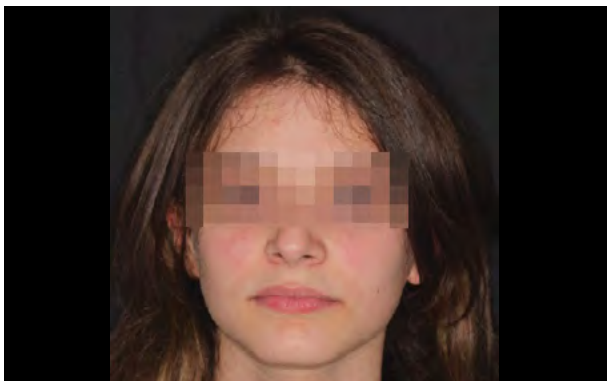
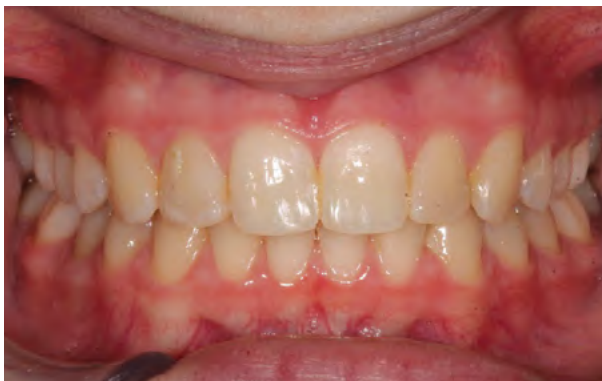
FIG. 19f



FIG. 19g

**JUNE 2023**



FIGG. 20a-c - Follow-up visit after 27 months.

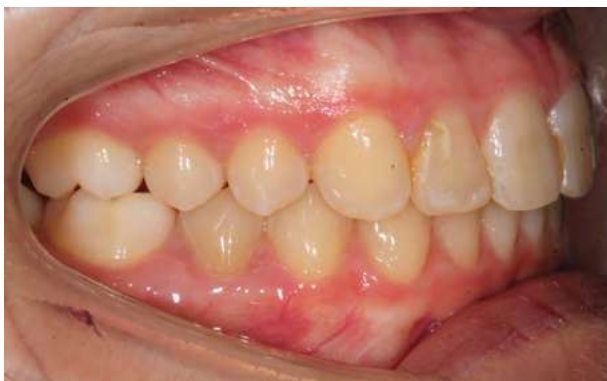

FIG. 20b

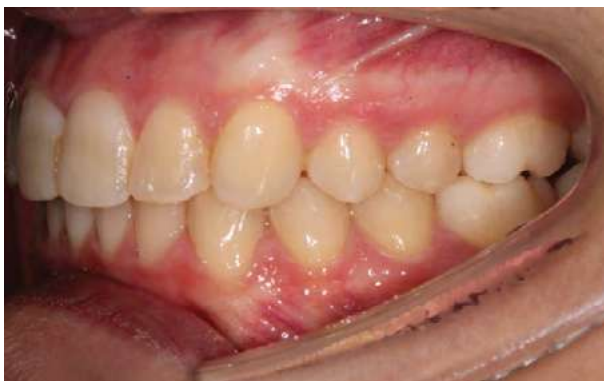

FIG. 20c

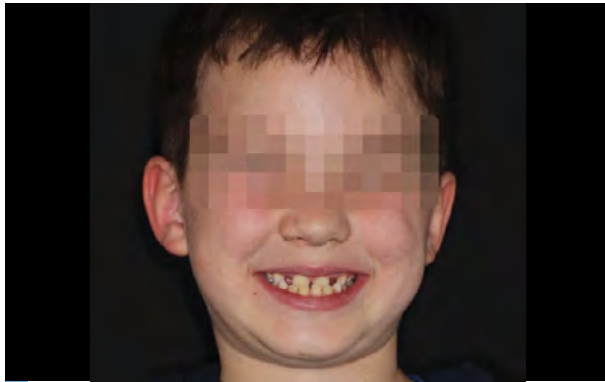### CASE 3

#### Antonio, 7 years, Use of the Leaf Expander for Anterior Functional Crossbite

Antonio at 7 years old, in the first stage of the dental transition he shows an anterior cross bite due to functional reasons. Class I cuspids and molars relationship.

After 3 months, the leaf Expander 450g of 6 mm solved the anterior crossbite.

The patient has been checked to follow-up the transition from deciduous to permanent dentition, which happened correctly.



FIGG. 21a-d -Beginning

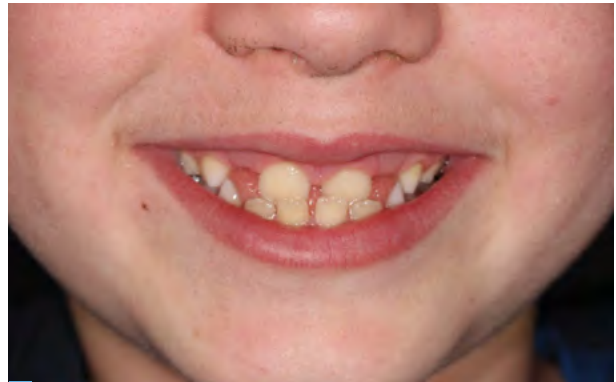

FIG. 21b

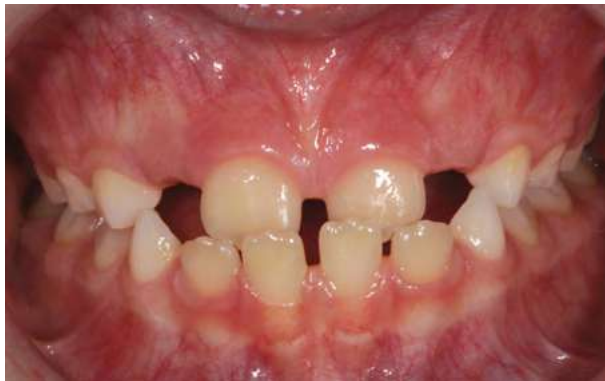

FIG. 21c

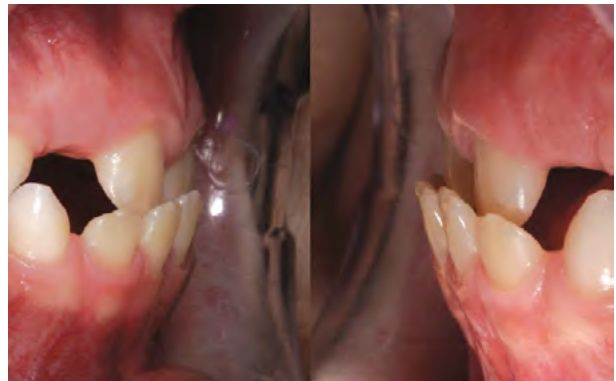
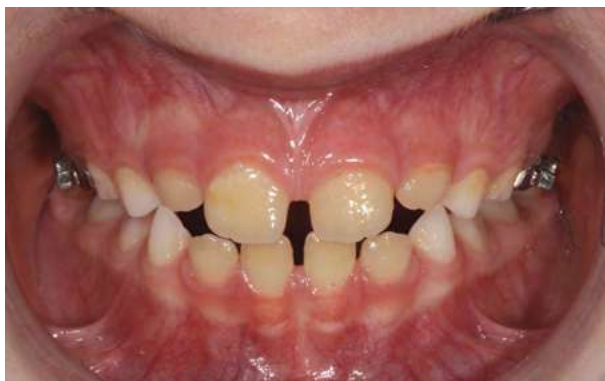
FIG. 21d

#### AFTER 3 MONTHS



FIGG. 22a-f - The anterior crossbite is solved after 3 months with Leaf expander 450g,6mm

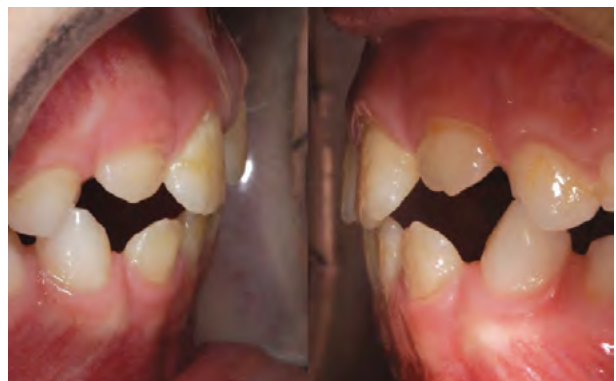

FIG. 22b

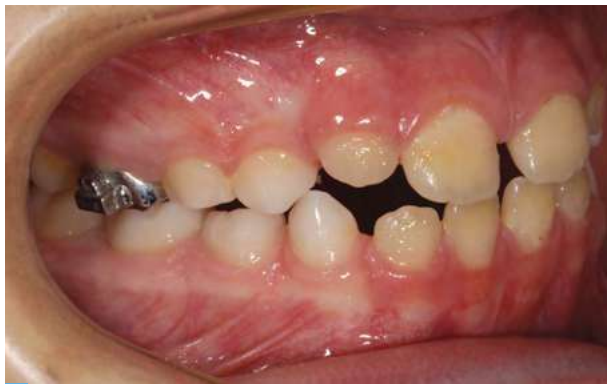

FIG. 22c

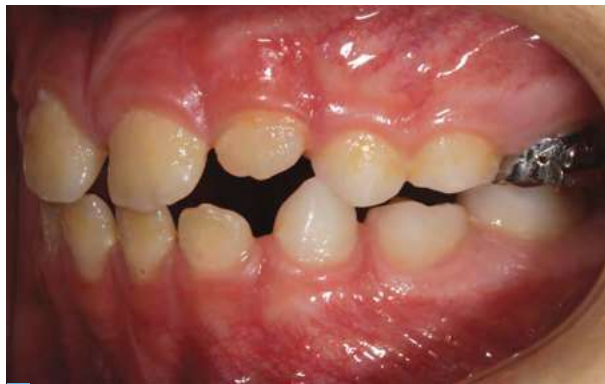

FIG. 22d

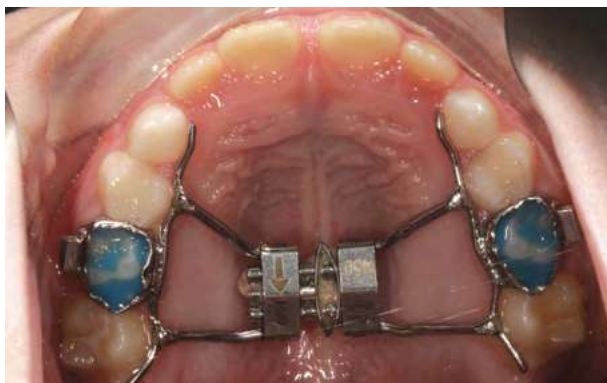

FIG. 22e

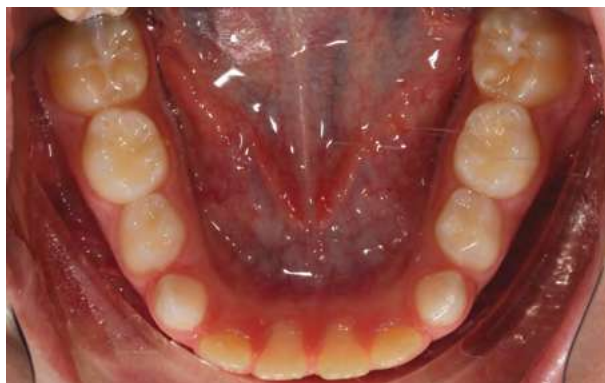

FIG. 22f

**AFTER 6 MONTH**

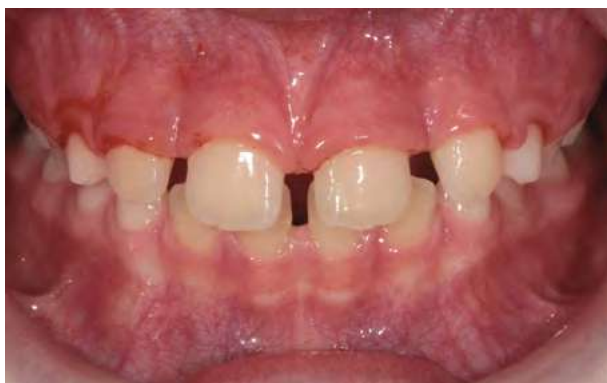

FIG. 23a-f - The leaf expander is removed, the first stage of the transition is completed

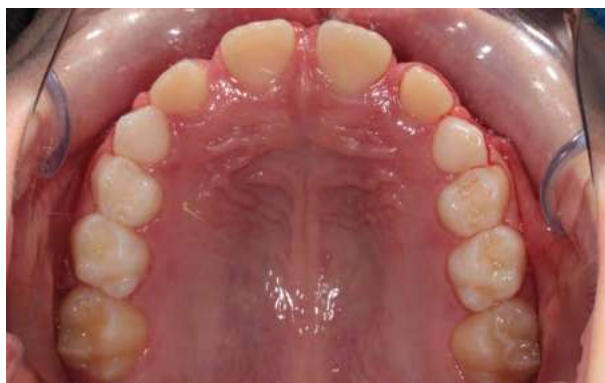

FIG. 23b

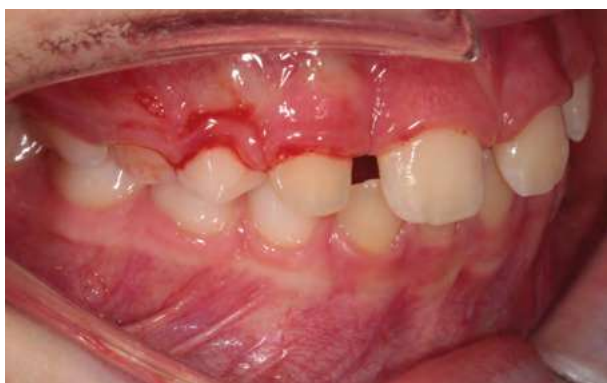

FIG. 23c

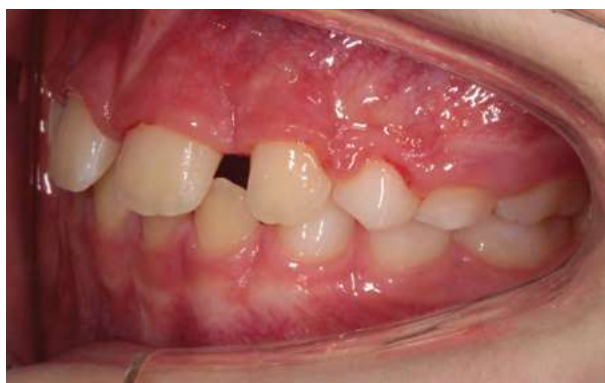

FIG. 23d



FIG. 23e

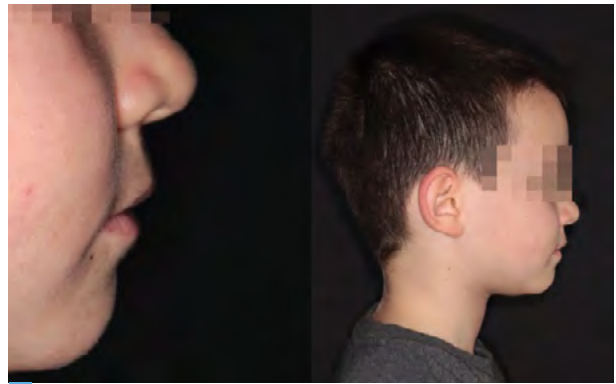
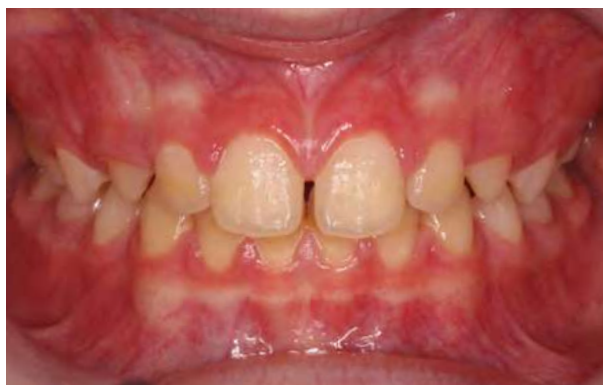
FIG. 23f

### END OF THE TREATMENT



FIGG. 24a-g - Dentition almost permanent.

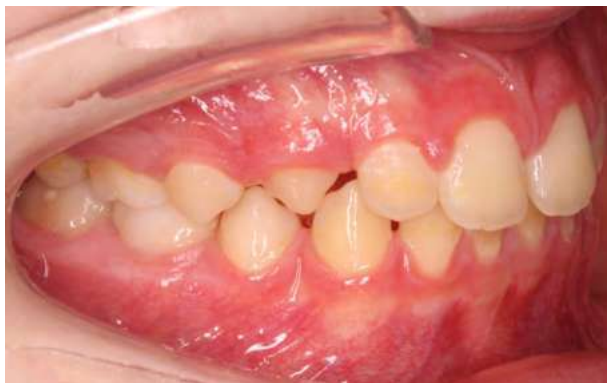

FIG. 24b

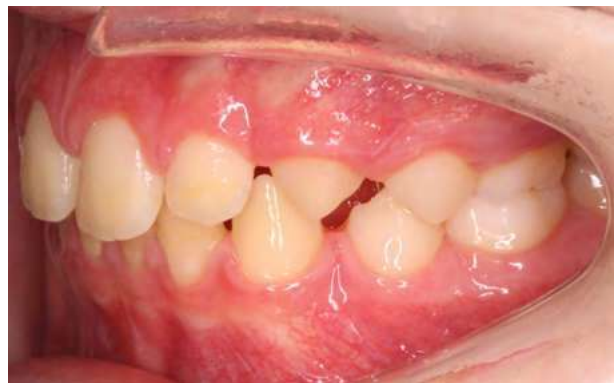

FIG. 24c

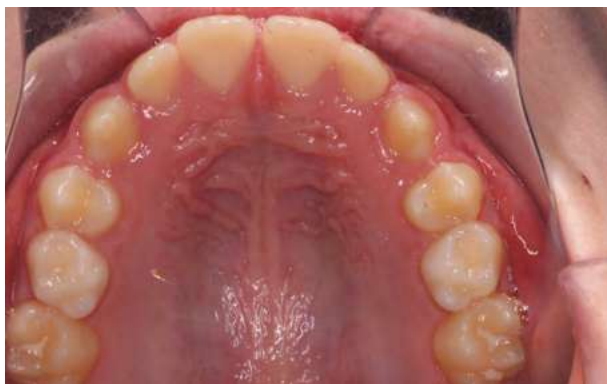

FIG. 24d

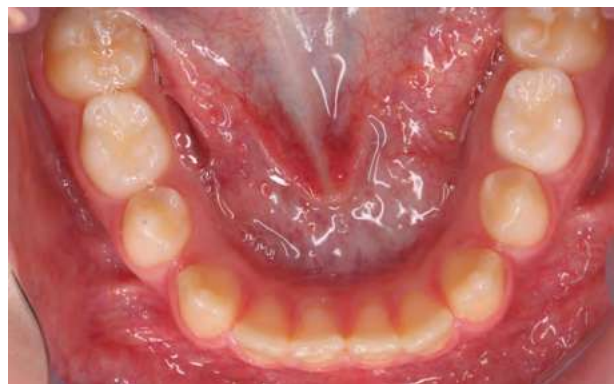

FIG. 24e

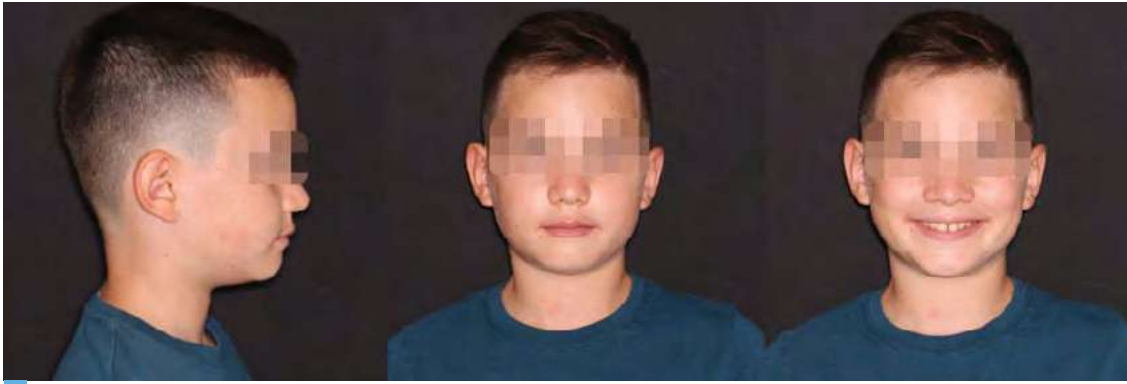

FIG. 24f

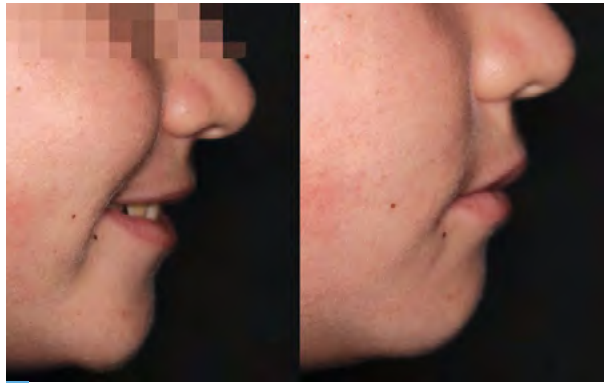

FIG. 24g



NEW GLOBAL IDENTITY





# THE LEAF EXPANDER® FOR THE TRANSVERS MAXILLARY CORRECTION IN ADULT PATIENTS

Authors:

**Alvise Caburlotto, Maria Elena Grecolini, Valentina Lanteri,  
Giada Maticena, Cristian Nocco**

Free translation from: "IL LEAF EXPANDER ® PER LA CORREZIONE TRASVERSALE DEL MASCELLARE NEL PAZIENTE ADULTO", Bollettino di informazioni Leone 110, October 2022. Authors: Alvise Caburlotto, Maria Elena Grecolini, Valentina Lanteri, Giada Maticena, Cristian Nocco

## INTRODUCTION

Maxillary transversal discrepancy in adult patients is a significant factor in many malocclusions, both dental and skeletal. Prevalence is at about 10% and often manifests as a unilateral or bilateral posterior cross-bite, with or without upper jaw dental crowding. The deficiency in transversal dimension is often associated with a narrow palate, lower arch dental crowding, buccal corridors, periodontal issues and dental erosion.

Achieving a proper skeletal and dental relationship is crucial to get a functional occlusion, and enhancing the smile aesthetic.

The gold standard treatment to correct maxillary skeletal deficiency is palatal expansion, that allows to increase the transversal width of the superior arch. At present, on the market, there are multiple devices available, differing in forces delivered during treatment with the aim of achieving maxillary expansion (Rapid palatal expansion or Slow palatal expansion); however, we must consider that the type of device can affect the results of the consequent treatment.

The possibility to obtain a skeletal palatal expansion decreases with age; when skeletal results are not totally or even partially achievable, Dental-alveolar expansion is the only feasible achievement with the use of palatal appliances.

The diagnosis represents the starting point for formulating the correct therapy. Therefore, it is important to evaluate the skeletal craniofacial features in terms of dimension analysis, and determining the

entity of expansion needed. Thus, the efficiency and effectiveness of treatment is increased.

After years of research and evolutions, the Leaf Expander® is considered an extremely valuable device for maxillary transversal deficiency correction.

The results of recent medical publications indicate that the Leaf Expander can be used, not only for orthodontic treatment in growing patients, but also in adults.

In this article, two case reports show the effectiveness of the Leaf expander to perform a dental-alveolar expansion on adult patients.

The two reports show adult patient cases, having Class II skeletal malocclusion with transversal deficiency (mild to moderate), and unilateral posterior cross-bite, solved by the use of Leaf Expander in combination with targeted orthodontic biomechanics and intermaxillary elastics.

## LEAF EXPANDER® EXPANSION SYSTEM

The expander structure seems the same as the standard rapid palatal expander, but the active device component features and the activation protocol are different. The screw does not act directly on the teeth but compresses the Ni-Ti leaf springs which, during de-activation phase, try to go back to their original shape returning in this way transversal expansion forces. The expander is available in two models, 450 g and 900 g and each one of these is available in two expansion capacities: 6 mm and 9 mm.

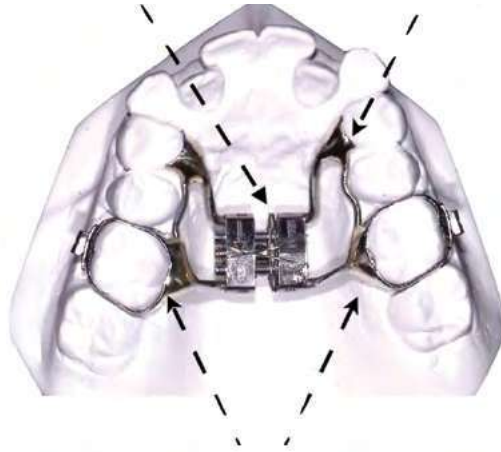


FIG. 1 Leaf demonstrative model




FIG. 2 - The number of the leaf springs determines the expansion.  
The thickness of the leaf springs determines the forces delivered (450 g or 900 g).

The adult patients selection to be treated with Leaf Expander, has been made based on the following criteria:

Inclusion Criteria for the study

- Patients ages range from 16 to 30 years
- Skeletal criteria: Class I, Class II with transversal deficit mild to moderate between 3-5mm
- Endo inclination of the posterior sectors
- No periodontal issues
- Patient refusal for surgical options such as SARPE or MARPE and tooth extractions

The leaf expander appliance must be anchored on orthodontic bands (standard or customized) of tooth elements 16-26 and extension arms up to 14-24.

At the cementation phase, the appliance is pre-activated, which means that, once the clinician removes the clip, the device will start to release the grams of force labeled on the body (based on the model used) without the patient's compliance. The subsequent activation will be made according to a specific activation protocol to allow a slow dental-alveolar expansion.

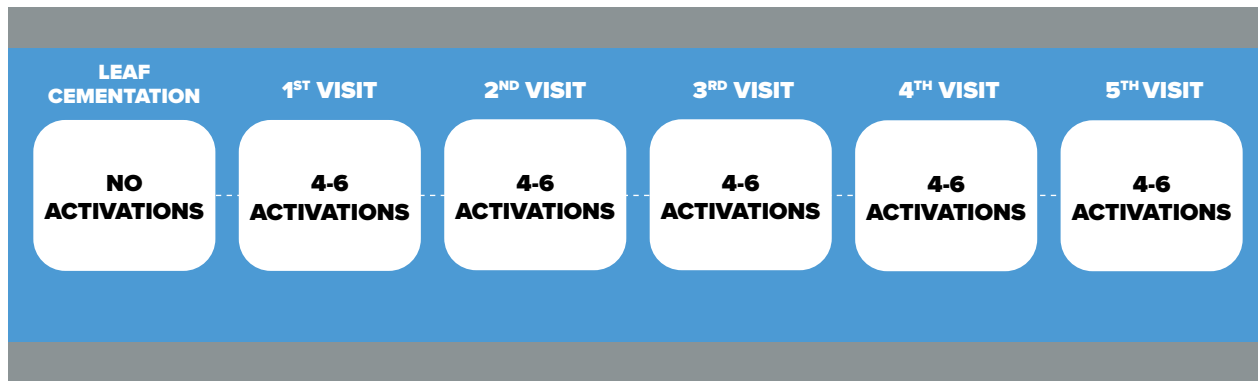


FIG. 3 - Leaf Expander® activation protocol suggested for adult patient treatment

The orthodontist will continue the appliance activations inside the dental office, based on the clinical needs, considering that every activation promotes 0,1 mm of springs re-compression.

Bonding of the lower arch is usually performed 1 month after delivery of the Leaf Expander, where the decompensation stage will immediately begin.

The upper arch is bonded upon the second follow up visit, when we leave in place the Leaf Expander and we place the multibracket system. The usage of the orthodontic mechanic of Class II through intermaxillary elastics, promotes both the correction of the molar class, and the spontaneous forward movement of the mandible, which is freed from the occlusal forces due to the contracted maxilla.

## CLINICAL CASE#1

### Initial situation:

- Female, Caucasian 17 years
- Hyperdivergent Class II Malocclusion
- Molar Occlusion Class I
- OVJ 5 mm of the superior incisors and decreased OVB
- Moderate dental crowding, upper and lower
- Shifted midline.

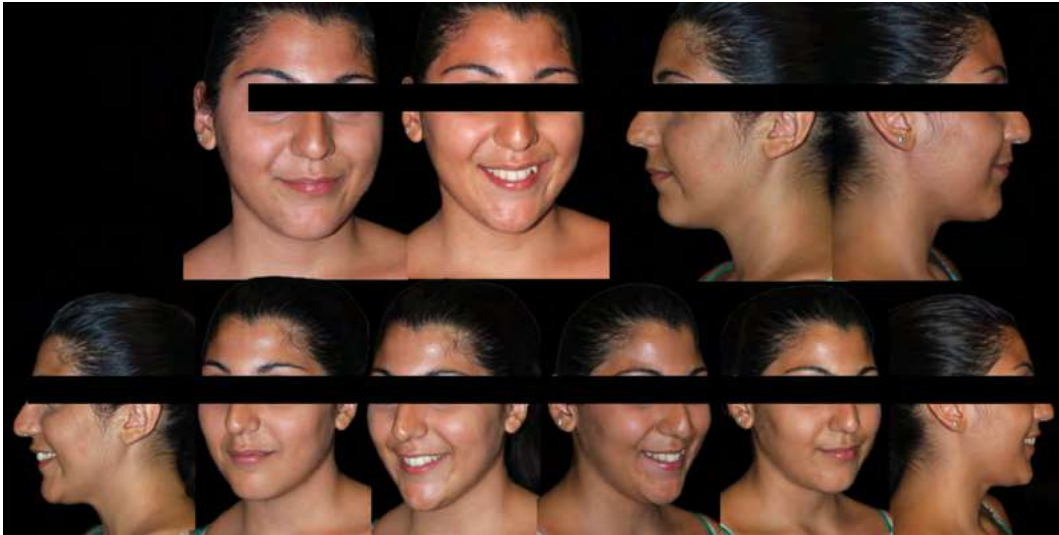

FIG. 4 - Facial pictures before treatment- facial features

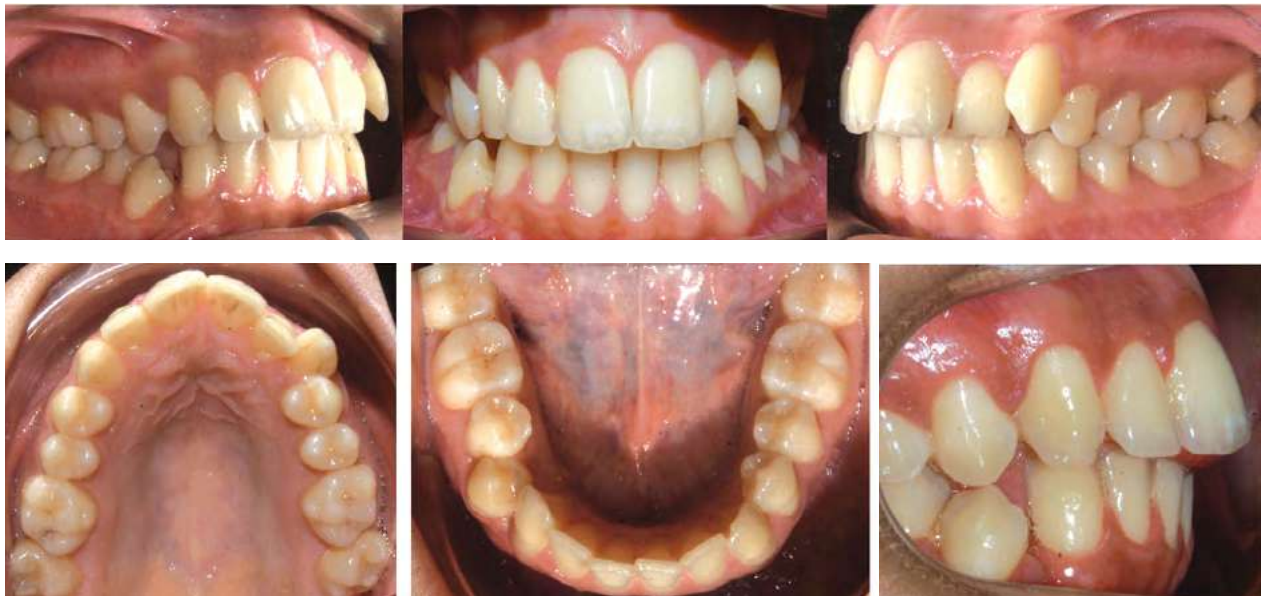

FIG. 5 - Intra-oral pictures before the treatment

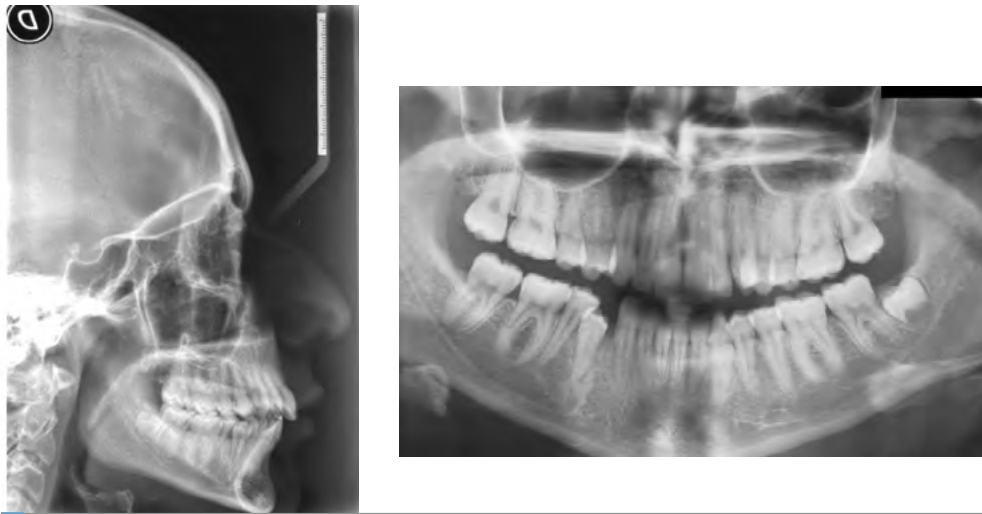



FIG. 6 - X-Ray before the treatment

### Comparison

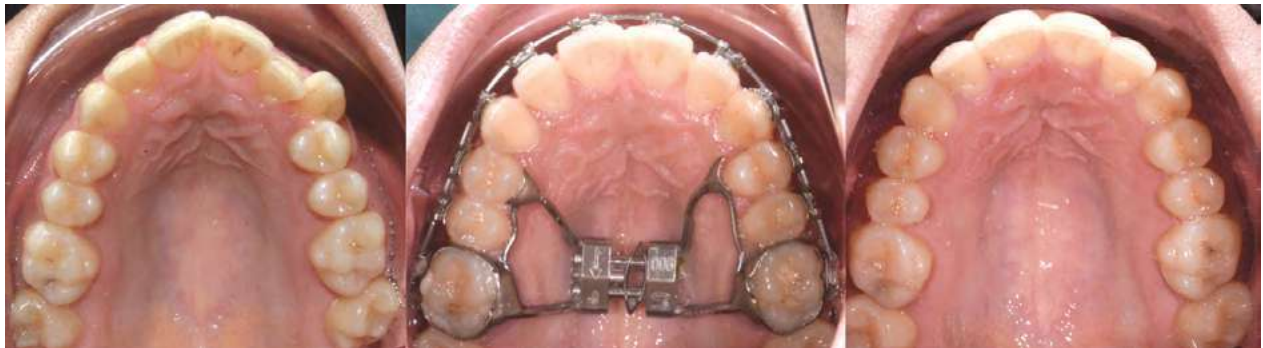

FIG. 7 - Upper Arch at the beginning, during and at the end of the treatment

### 24 months after the treatment



- Hyperdivergent skeletal pattern
- Molar Occlusion Class I
- OVJ 2,5mm, OVB 2,5mm, midline alignment
- Transversal Discrepancy solved

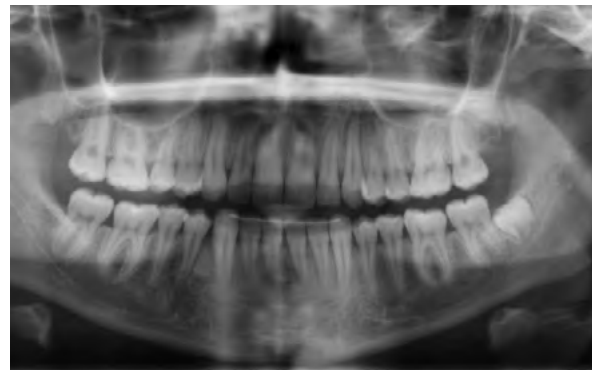
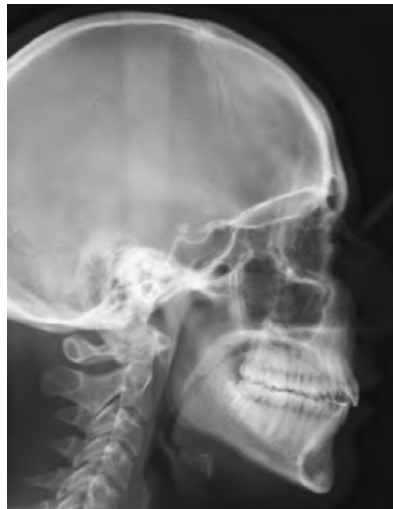
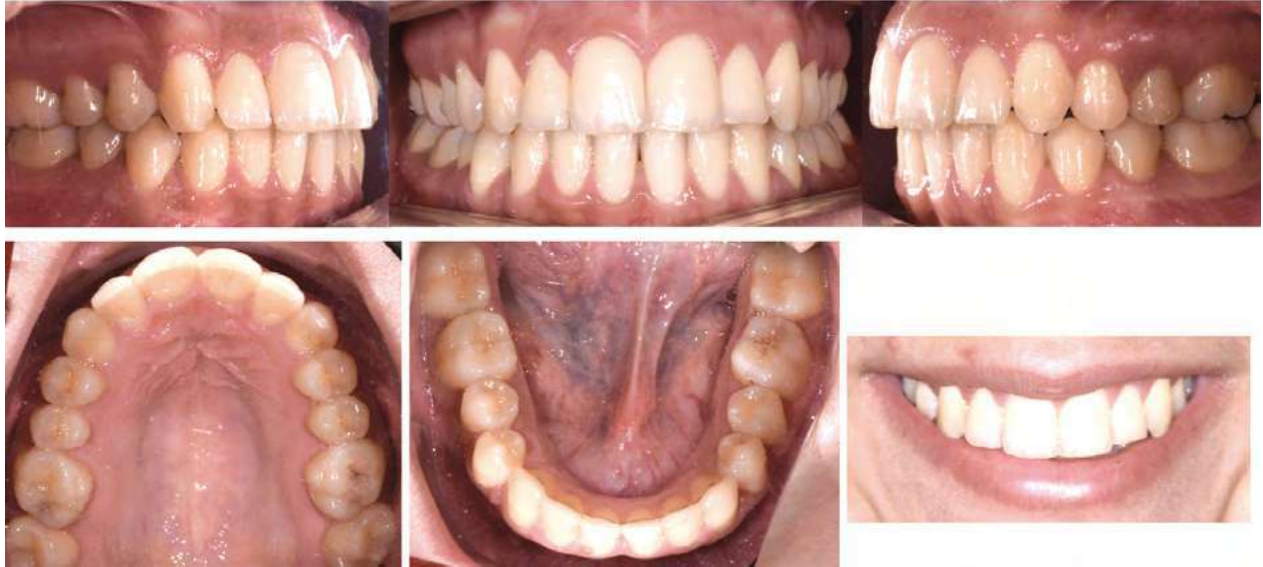
FIG. 8 - Final situation: intra-oral pictures and X-Rays after the treatment.

## CLINICAL CASE #2

### Initial situation

- Female, Caucasian, 30 years and 6 months
- Hyperdivergent Class II Malocclusion, due to posterior rotation of the mandible, molar Class II occlusion
- Cross-bite for dental elements 16 and 17
- Dental Class I on left side
- Proclination of superior incisors OVJ 6 mm
- Severe crowding of upper and lower incisors
- Spee and Wilson curves too marked
- Midline shifted to right
- Moderate transverse maxillary discrepancy with lateral and posterior teeth endo-inclination

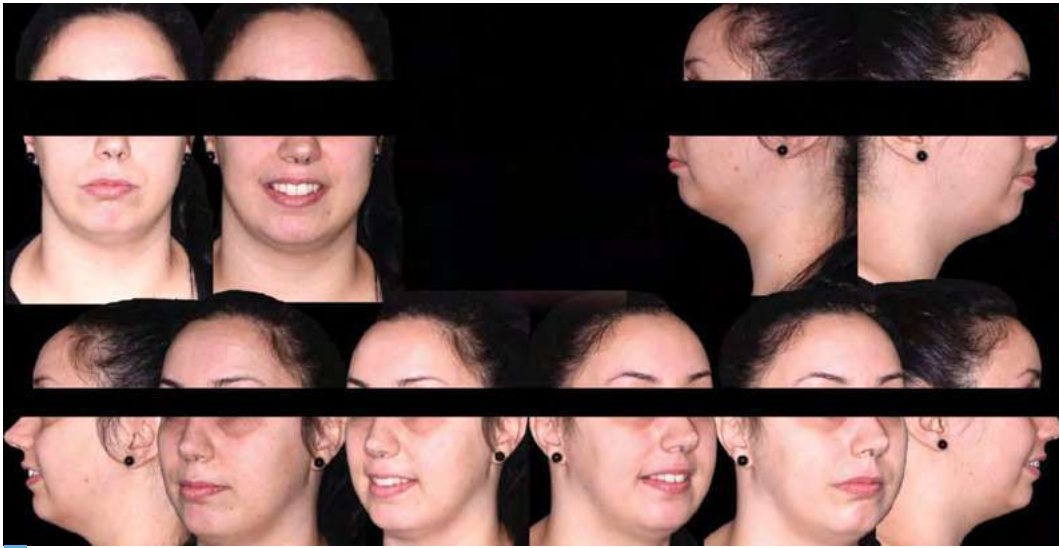

FIG. 9 - Facial features before the treatment

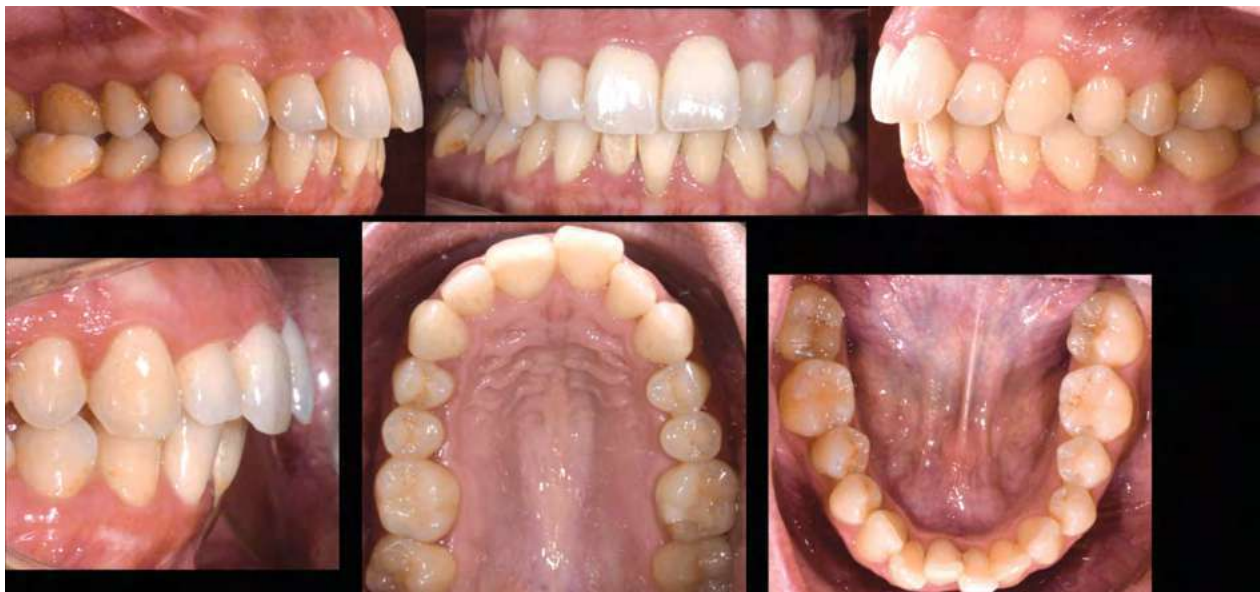

FIG. 10 - Intra-oral pictures before the treatment

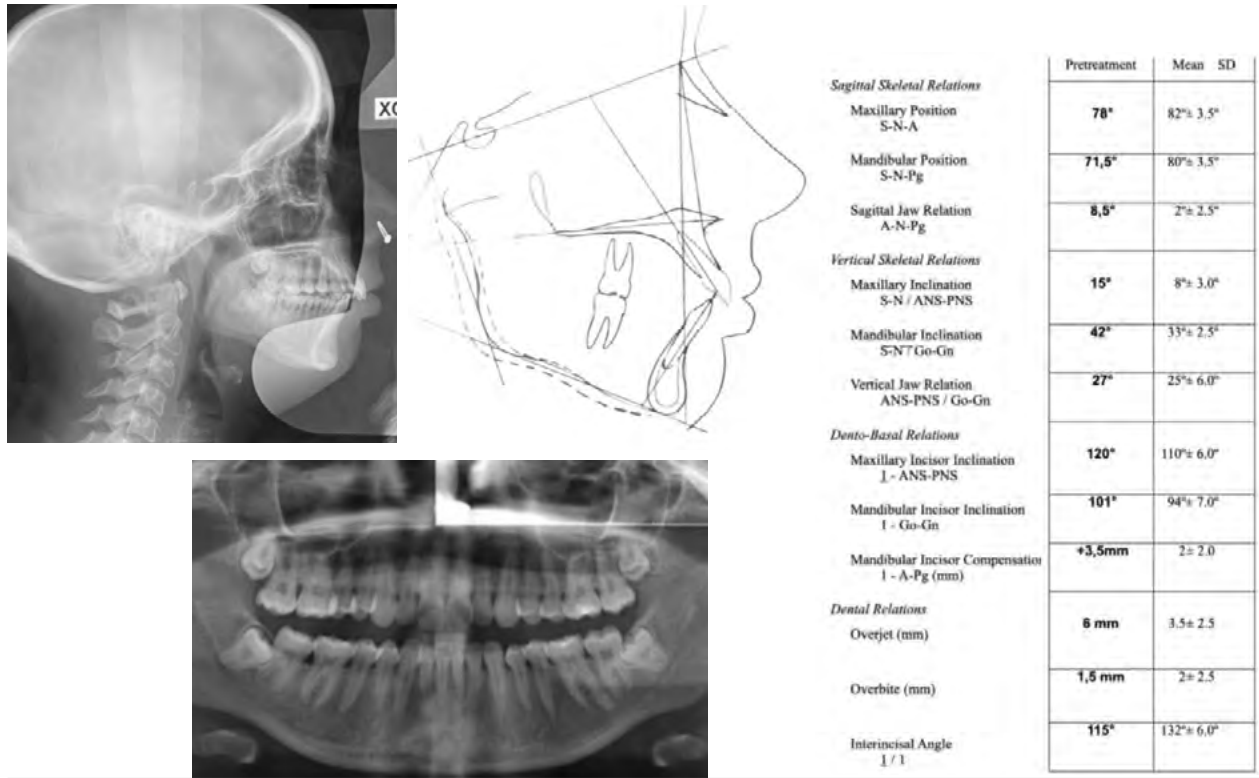


FIG. 11 - X-Ray and cephalometric data before the treatment

### 24 months after the treatment

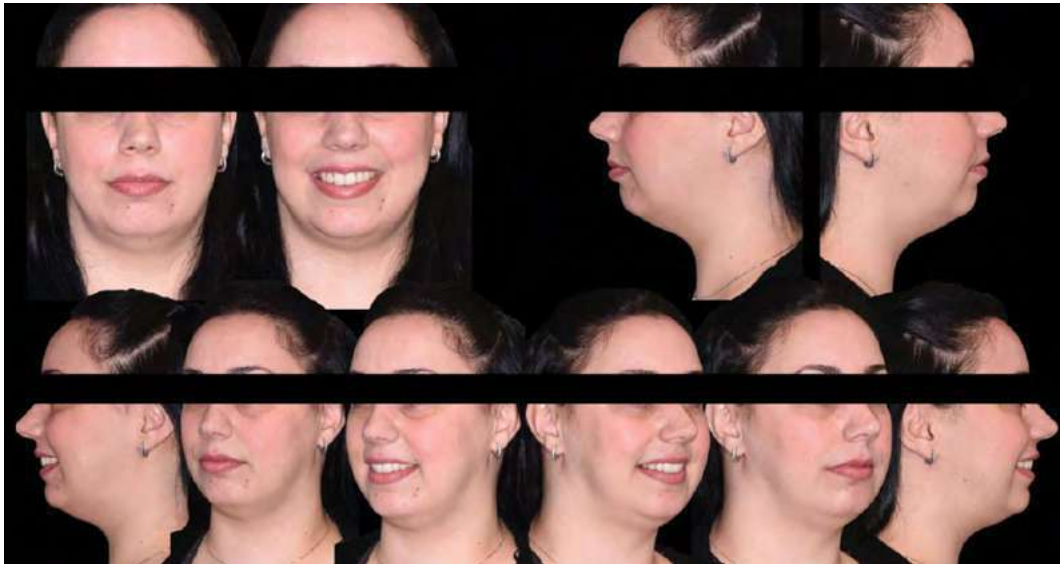

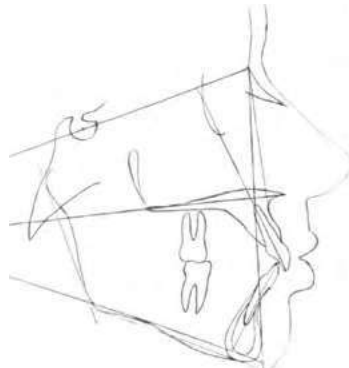
FIG.12 - Facial features 24 months after the treatment



- Hyperdivergent Class II Skeletal pattern
- Improvement of the skeletal class II thanks to the mandible rotation
- Right and Left Class I molar occlusion
- OVJ 3 mm
- Spee and Wilson curve decrease
- Midline aligned
- Standard transverse size of the maxilla.

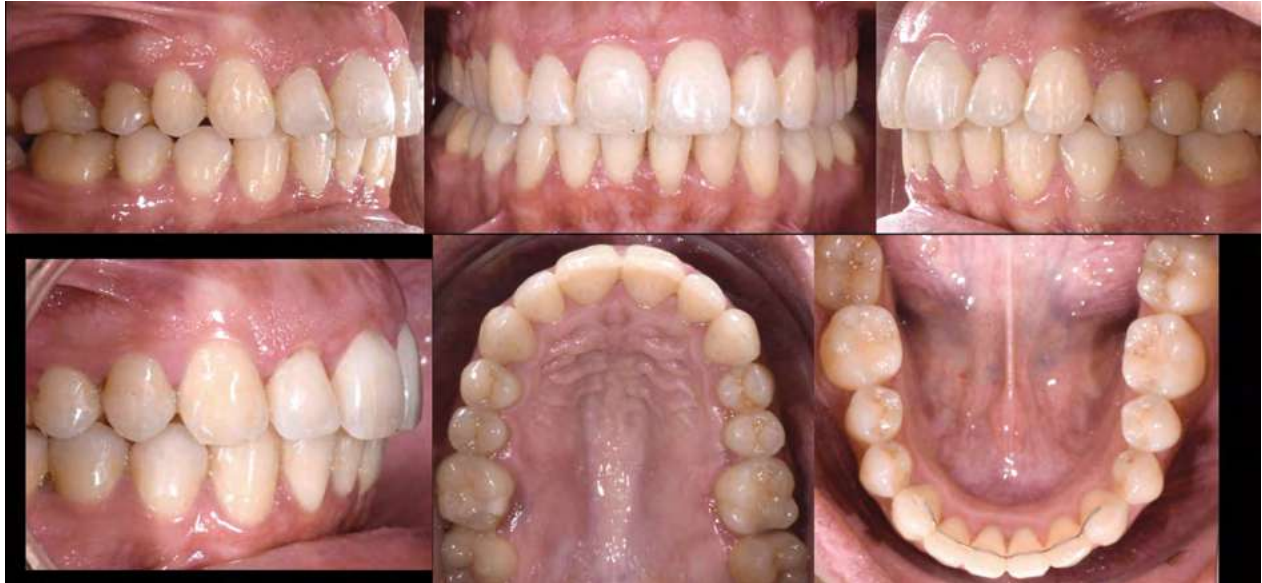
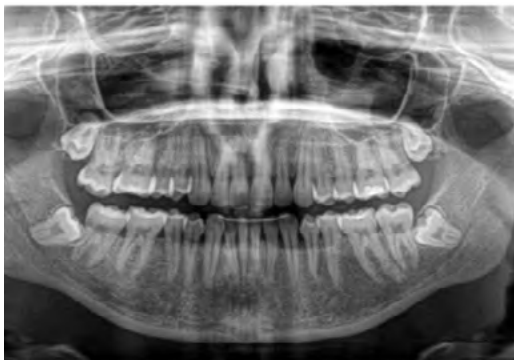
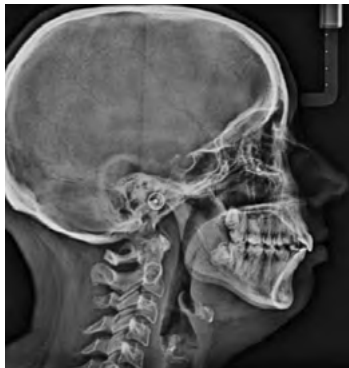FIG. 13- Intra-oral pictures after 24 months



	Pretreatment	Posttreatment	Mean SD
<i>Sagittal Skeletal Relations</i>			
Maxillary Position S-N-A	78°	78°	82°± 3.5°
Mandibular Position S-N-Pg	71,5°	73,5°	80°± 3.5°
Sagittal Jaw Relation A-N-Pg	8,5°	4,5°	2°± 2.5°
<i>Vertical Skeletal Relations</i>			
Maxillary Inclination S-N / ANS-PNS	15°	14°	8°± 3.0°
Mandibular Inclination S-N / Go-Gn	42°	39,5°	33°± 2.5°
Vertical Jaw Relation ANS-PNS / Go-Gn	27°	25,5°	25°± 6.0°
<i>Dento-Basal Relations</i>			
Maxillary Incisor Inclination I - ANS-PNS	120°	110°	110°± 6.0°
Mandibular Incisor Inclination I - Go-Gn	101°	96°	94°± 7.0°
Mandibular Incisor Compensation I - A-Pg (mm)	+3,5mm	2 mm	2± 2.0
<i>Dental Relations</i>			
Overjet (mm)	6 mm	3 mm	3.5± 2.5
Overbite (mm)	1,5 mm	2,5 mm	2± 2.5
Intercuspal Angle I / I	115°	128°	132°± 6.0°

FIG. 14 - X-Ray and cephalometric data before the treatment

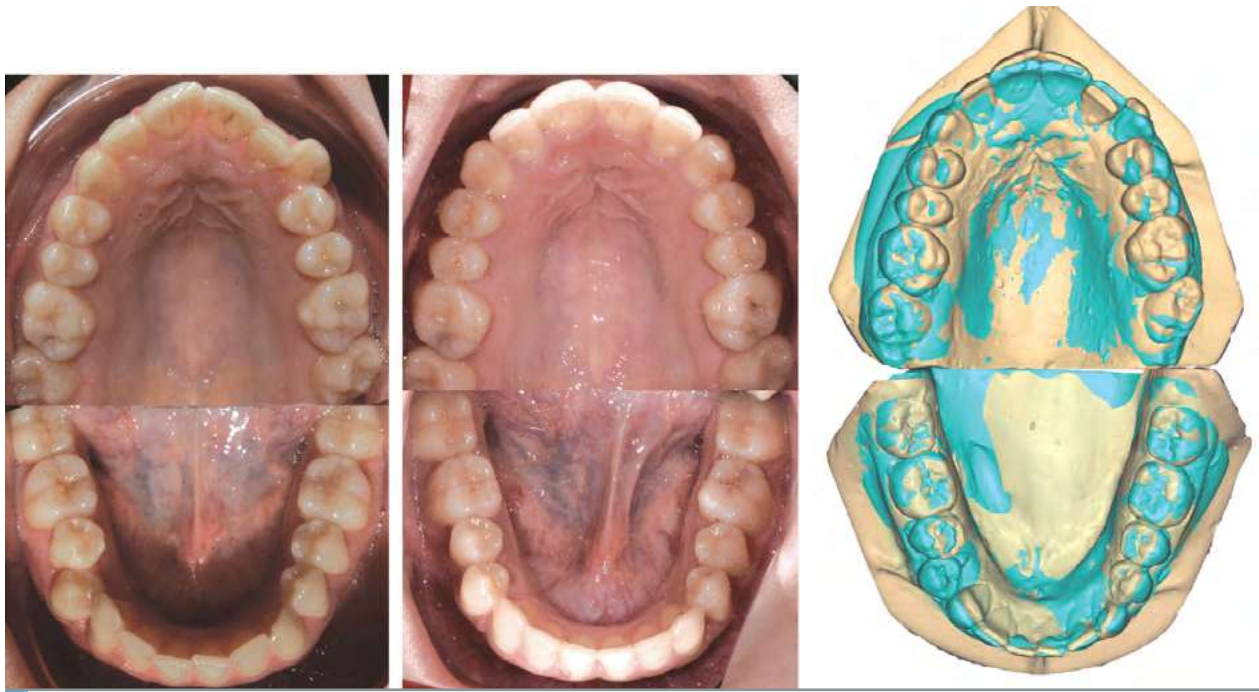


FIG. 15 - Superimposition of digital models before and after treatment clinical case 1

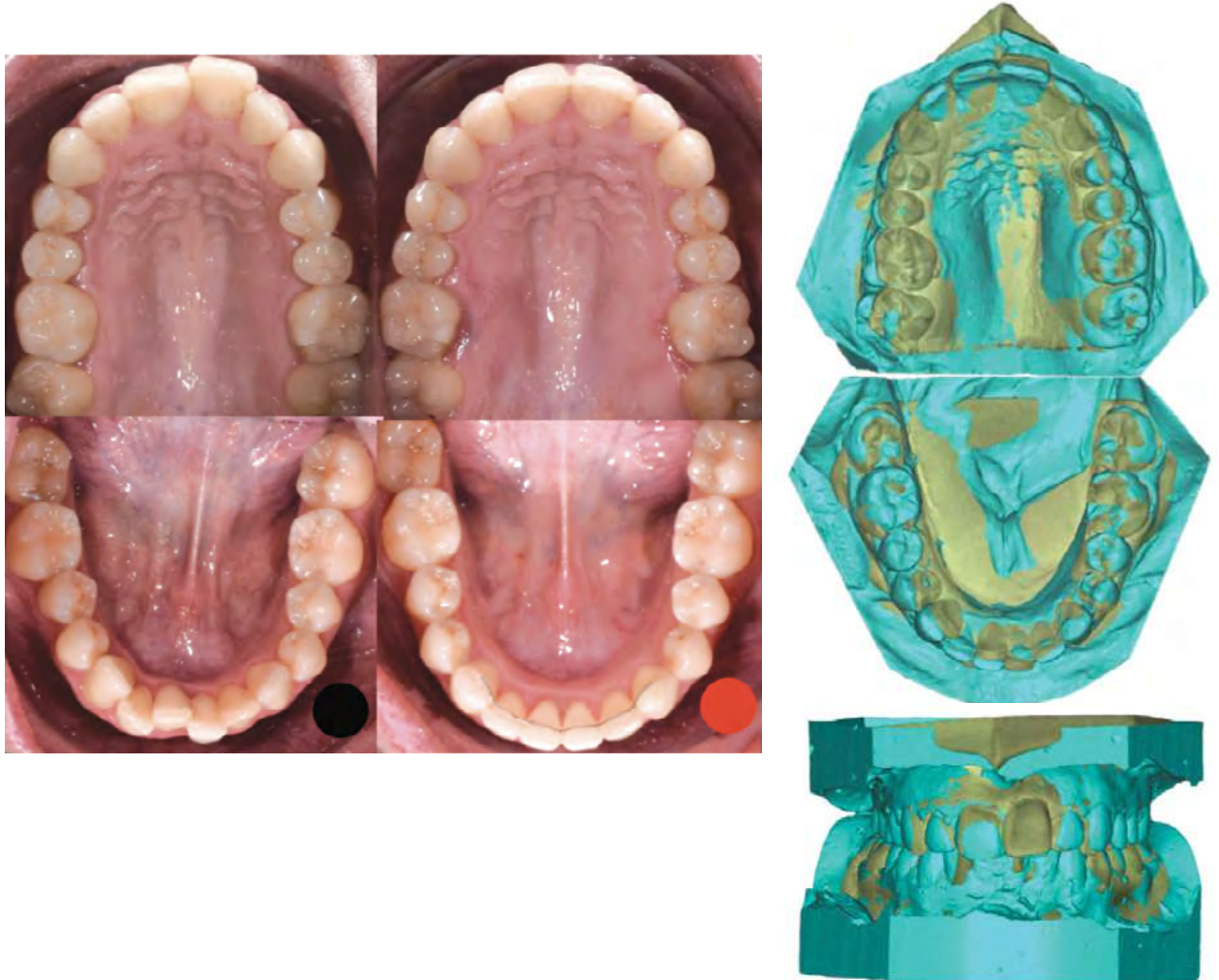


FIG. 16 - Superimposition of digital models before and after treatment clinical case 2

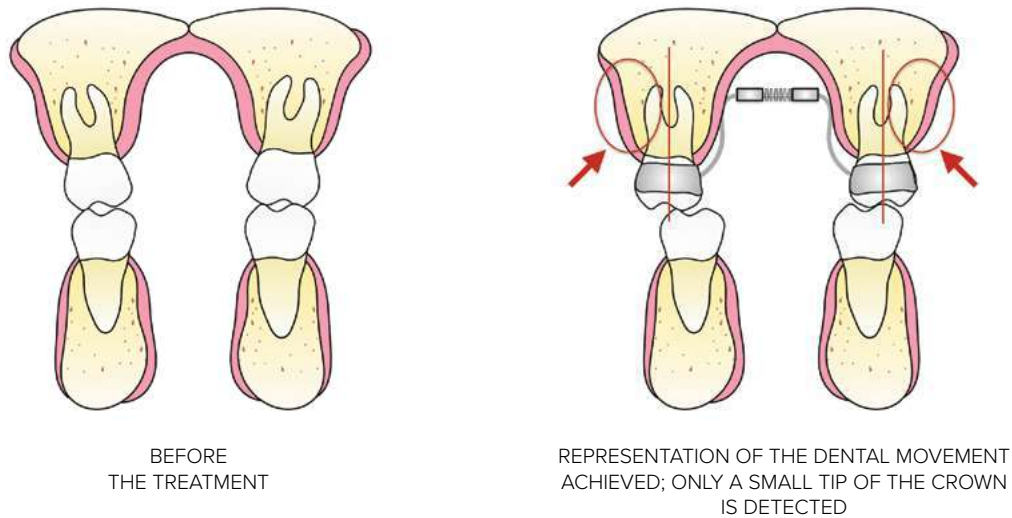


FIG. 17 - Representation of the Leaf expander action

## CONCLUSION

The Leaf expander is the ideal device to achieve a maxillary orthodontic expansion by means of calibrated and constant forces usage. This device creates an equilibrated maxillary dental-alveolar expansion through body movement of the teeth; moreover, the controlled movements of the lateral and posterior sectors of the maxilla, avoid the dental flaring phenomenon. There are multiple advantage with the use of this device

- Easy activation, as a result of the visibility of the active part
- Safe use
- No home activation and patient compliance
- Results predictability

Expansion action performed by Leaf Expander is a therapeutic choice, used to solve moderate transverse maxillary discrepancy in Class I, Class II and Class III malocclusion.

The use of Leaf expander in adult patients is alike the use of other devices as expanders and Quad Helix, multi-brackets appliances but stands out with it's increased advantages and safety.

The two clinical cases presented in this article proves that the use of the Leaf Expander has been fundamental to obtain the results of the treatment, since it has allowed decompensation of the dental arches.

After maxillary expansion and correction of endo inclination to the posterior teeth, done with targeted orthodontic biomechanics, it is also possible to appreciate anterior rotation of the mandible; movement that, as reported by clinical evidence, helps to correct the Skeletal Class II malocclusion.

## BIBLIOGRAFIA

- 1) Cephalometric study of slow maxillary expansion in adults. Yanli Cao, Yanheng Zhou, Yang Song, and Robert L. Vanarsdall, Jr.
- 2) Changes in clinical crown height as a result of transverse expansion of the maxilla in adults. Turi Bassarelli, Michel Dalstra and Birte Melsen. *European Journal of Orthodontics* 27 (2005) 121-128 doi: 10.1093/ejo/cjh045.
- 3) Orthodontic treatment for posterior crossbites (review). Agostino P, Ugolini A, Signori A, Silvestrini-Biavati A, Harrison JE, Riley P. *The Cochrane Collaboration*. Published by John Wiley & Sons, Ltd.
- 4) Dental and skeletal effects of palatal expansion techniques: a systematic review of the current evidence from systematic reviews and meta- analyses. R.Bucci, V. D'Antò, R.Rongo, R. Valletta, R. Martina & A. Michelotti. *Journal of Oral Rehabilitation* 2016 43; 543-564
- 5) Dental and skeletal effects of palatal expansion techniques: a systematic review of the current evidence from systematic reviews and meta- analyses. R.Bucci, V. D'Antò, R.Rongo, R. Valletta, R. Martina & A. Michelotti. *Journal of Oral Rehabilitation* 2016 43; 543-564.
- 6) Diagnostic methods for assessing maxillary skeletal and dental transverse deficiencies: a systematic review. Dena Sawchuk, Kris Currie, Manuel Lagravere Palomo, Carlos Flores-Mir. *The Korean Journal of Orthodontics*.
- 7) Buccal bone changes around first permanent molars and second primary molars after maxillary expansion with a low compliance Ni-Ti Leaf Spring Expander. Valentina Lanteri, Davide Cavagnetto, Andrea Abate, Eleonora Mainardi, Francesca Gaffuri, Alessandro Ugolini and Cinzia Maspero. *International Journal of Environmental Research and Public Health*.
- 8) Comparison between two screws for maxillary expansion: a multicenter randomized controlled trial on patient's reported outcome measures. Michele Nieri, Valeria Paoloni, Roberta Lione, Valeria Barone, Matilde Marino Merlo Jr, Veronica Giuntini, Paola Cozza, and Lorenzo Franchi. *European Journal of Orthodontics*, 2021, 293-300.
- 9) Non surgical rapid maxillary alveolar expansion in adults: a clinical evaluation. Chester S. Handelman, DMD. *The Angle Orthodontist*, Vol. 67 No.4 1997.
- 10) The effectiveness of non -surgical maxillary expansion: a meta- analysis. Yang Zhou, Hu Long, Niansong Ye, Junjie Xue, Xin Yang, Lina Liao and Wenli Lai. *European Journal of Orthodontics* 36 (2014) 233-242.

# New Catalog 2024

Laboratory  
Products

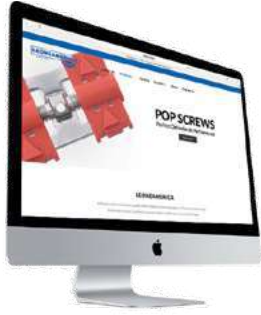

Scan here&download

Clinical  
Products



Scan here&download



### LEONEAMERICA.COM

LeoneAmerica Dental Products, Inc. is delighted to introduce our upgraded website, **leoneamerica.com**. Products can be searched by orthodontics, pediatrics, or sleep apnea specialties, making the task of finding the perfect treatment solution even easier. We are so pleased to introduce this site as an interactive and useful tool for our clinical and laboratory customers.



### THROUGH TRUSTED SELLERS

Leone products are available through a number of trusted dealers throughout the United States. For more information on how to purchase Leone products, please call us at **(805) 487-9860** or visit us online at **leoneamerica.com**



### LEOLAB USA

Certified Leolab partners work closely with LeoneAmerica to bring you the best of research, innovation, and quality. The collaboration between specialized orthodontic experience and top-tier orthodontic manufacturing help to bring together some of the most precise orthodontic appliances on the market today.

**leolabusa.com**



### ORTHODONTIC RESOURCE GROUP

LeoneAmerica Dental Products, Inc. is proud to announce itself as a corporate sponsor of the Orthodontic Resource Group. This collaborative group focuses on fostering relationships between orthodontic professionals, and moving the field of orthodontics together as a whole.

**orthodonticresource.com**

### ASK FOR LEONEAMERICA CATALOG



### Dental Products Inc.

1641 S. Rose Avenue Oxnard, CA 93033  
(805) 487-9860 • info@leoneamerica.com • **leoneamerica.com**

LeoneAmerica is the sole distributor of Leone Orthodontic products in the United States, Canada and Puerto Rico.

**LEONE**  
ORTHODONTIC  
SYMPOSIUM

**NEW YORK CITY**  
SATURDAY,  
SEPTEMBER 7  
2024

# CONTEMPORARY METHODS FOR SPACE GAINING



**LEAF EXPANDER:  
SIMPLIFYING  
INTERCEPTIVE  
TREATMENT FOR  
PATIENTS  
AND PARENTS**

DR. NICOLAS FREDA



**THE USE OF  
LEAF EXPANDER  
IN ADULT  
PATIENTS**

DR. MARIA ELENA  
GRECOLINI



**ADULT PALATAL  
EXPANSION:  
OVERCOMING  
CURRENT  
LIMITATIONS BY THE  
USE OF TADs**

DR. GIUSEPPE PERINETTI



**MORE INFO  
AND REGISTRATION**



## ABOUT THE CONFERENCE

Lack of space is one of the most common problems in orthodontics.

The speakers will address this issue by presenting the latest scientific and clinically proven therapies according to the age of the patient. The clinical results of a unique spring-loaded expander and appliances anchored to TADs will be presented in detail, as well as digital workflow production in the laboratory.

## PROGRAM

8:00 am

**Registration**

9:00 am

**Introduction by Prof. Olivier Nicolay**

9:15 am

### **LEAF EXPANDER: SIMPLIFYING INTERCEPTIVE TREATMENT FOR PATIENTS AND PARENTS**

DR. NICOLAS FREDA

Outline:

- Review the benefits of phase I/interceptive treatment for space creation in adolescents.
- Introduce the Leaf Expander and Leaf Self-Expander.
- Review benefits of Leaf for patients, parents and practitioners and how they pair with 3D printed (sintered) bands.
- Case presentations including insertion/removal of appliances.

10:20 am

### **THE USE OF LEAF EXPANDER IN ADULT PATIENTS**

DR. ELENA GRECOLINI

Outline:

- Introduction to aesthetic needs and growing demand for adult orthodontic treatment.
- Leaf Expander's role in effectively addressing transversal maxillary hypoplasia.
- Technological versatility of Leaf Expander for gradual and safe maxillary expansion.
- Clinical outcomes and bone stability: CBCT analysis.

- Conclusion: Leaf Expander's efficacy in preserving dental and bone health.

11:30 am

**Laboratory nuances for fixed appliance fabrication**

12:00 pm - 1:00 pm

**Lunch**

1:00 pm – 3:00 pm

### **ADULT PALATAL EXPANSION: OVERCOMING CURRENT LIMITATIONS BY THE USE OF TADs**

DR. GIUSEPPE PERINETTI

Outline:

- Palatal expansion in adolescent and adult patients: predictability, protocols, failure management and comparison with surgical expansion.
- Digital orthodontics aid in palatal anchorage: advantages and when it is strictly necessary.

### **MORE INFO AND REGISTRATION**



VENUE:

**NYU COLLEGE OF DENTISTRY**

345 E. 24TH STREET (CORNER OF FIRST AVENUE),  
NEW YORK, NY, UNITED STATES

# ORTHONEWS

SPRING / SUMMER 2024  
VOL 1 #44

PSRST STD  
MAIL  
U.S. POSTAGE  
PAID  
OXNARD, CA  
PERMIT NO. 1031

A PERIODICAL FOR ORTHODONTIC PROFESSIONALS

Booth#227



## MAY 17, 2024

AADSM  
(American Academy  
of Dental Sleep Medicine)  
HYATT REGENCY NEW ORLEANS

## CONTEMPORARY METHODS FOR SPACE GAINING

## SEPTEMBER 7 2024

Symposium Leoneamerica 2024  
NYU COLLEGE OF DENTISTRY  
345 E. 24th Street (corner of First Avenue),  
New York, NY, United States, New York

WO  
CON | WESTERN  
ORTHODONTIC  
CONFERENCE  
ANNUAL  
SESSION



## NOVEMBER 14 – 17 2024

The Westin Rancho Mirage Golf – Resort & SPA  
Palm Springs, CA

# Leone<sup>®</sup> America

LEONEAMERICA.COM